

CLINICAL PRACTICE GUIDELINES

MARTIN J. KELLEY, DPT • MICHAEL A. SHAFFER, MSPT • JOHN E. KUHN, MD • LORI A. MICHENER, PT, PhD
AMEE L. SEITZ, PT, PhD • TIMOTHY L. UHL, PT, PhD • JOSEPH J. GODGES, DPT, MA • PHILIP W. MCCLURE, PT, PhD

Shoulder Pain and Mobility Deficits: Adhesive Capsulitis

Clinical Practice Guidelines Linked to the International Classification of Functioning, Disability, and Health From the Orthopaedic Section of the American Physical Therapy Association

J Orthop Sports Phys Ther 2013;43(5):A1-A31. doi:10.2519/jospt.2013.0302

RECOMMENDATIONS.....	A2
INTRODUCTION.....	A3
METHODS.....	A4
CLINICAL GUIDELINES: <i>Impairment/Function-Based Diagnosis</i>	A6
CLINICAL GUIDELINES: <i>Examination</i>	A14
CLINICAL GUIDELINES: <i>Interventions</i>	A16
SUMMARY OF RECOMMENDATIONS.....	A26
AUTHOR/REVIEWER AFFILIATIONS AND CONTACTS.....	A27
REFERENCES.....	A28

REVIEWERS: Roy D. Altman, MD • John DeWitt, DPT • George J. Davies, DPT, MEd, MA
Todd Davenport, DPT • Helene Fearon, DPT • Amanda Ferland, DPT • Paula M. Ludewig, PT, PhD • Joy MacDermid, PT, PhD
James W. Matheson, DPT • Paul J. Roubal, DPT, PhD • Leslie Torburn, DPT • Kevin Wilk, DPT

For author, coordinator, contributor, and reviewer affiliations, see end of text. Copyright ©2013 Orthopaedic Section, American Physical Therapy Association (APTA), Inc, and the *Journal of Orthopaedic & Sports Physical Therapy*. The Orthopaedic Section, APTA, Inc, and the *Journal of Orthopaedic & Sports Physical Therapy* consent to the reproduction and distribution of these guidelines for educational purposes. Address correspondence to: Joseph Godges, DPT, ICF Practice Guidelines Coordinator, Orthopaedic Section, APTA, Inc, 2920 East Avenue South, Suite 200, La Crosse, WI 54601. E-mail: icf@orthopt.org

Recommendations

PATHOANATOMICAL FEATURES: Clinicians should assess for impairments in the capsuloligamentous complex and musculotendinous structures surrounding the shoulder complex when a patient presents with shoulder pain and mobility deficits (adhesive capsulitis). The loss of passive motion in multiple planes, particularly external rotation with the arm at the side and in varying degrees of shoulder abduction, is a significant finding that can be used to guide treatment planning. (Recommendation based on theoretical/foundational evidence.)

RISK FACTORS: Clinicians should recognize that (1) patients with diabetes mellitus and thyroid disease are at risk for developing adhesive capsulitis, and (2) adhesive capsulitis is more prevalent in individuals who are 40 to 65 years of age, female, and have had a previous episode of adhesive capsulitis in the contralateral arm. (Recommendation based on moderate evidence.)

CLINICAL COURSE: Clinicians should recognize that adhesive capsulitis occurs as a continuum of pathology characterized by a staged progression of pain and mobility deficits and that, at 12 to 18 months, mild to moderate mobility deficits and pain may persist, though many patients report minimal to no disability. (Recommendation based on weak evidence.)

DIAGNOSIS/CLASSIFICATION: Clinicians should recognize that patients with adhesive capsulitis present with a gradual and progressive onset of pain and loss of active and passive shoulder motion in both elevation and rotation. Utilizing the evaluation and intervention components described in these guidelines will assist clinicians in medical screening, differential evaluation of common shoulder musculoskeletal disorders, diagnosing tissue irritability levels, and planning intervention strategies for patients with shoulder pain and mobility deficits. (Recommendation based on expert opinion.)

DIFFERENTIAL DIAGNOSIS: Clinicians should consider diagnostic classifications other than adhesive capsulitis when the patient's reported activity limitations or impairments of body function and structure are not consistent with the diagnosis/classification section of these guidelines, or when the patient's symptoms are not resolving with interventions aimed at normalization of the patient's impairments of body function. (Recommendation based on expert opinion.)

EXAMINATION – OUTCOME MEASURES: Clinicians should use validated functional outcome measures, such as the Disabilities of the Arm, Shoulder and Hand (DASH), the American

Shoulder and Elbow Surgeons shoulder scale (ASES), or the Shoulder Pain and Disability Index (SPADI). These should be utilized before and after interventions intended to alleviate the impairments of body function and structure, activity limitations, and participation restrictions associated with adhesive capsulitis. (Recommendation based on strong evidence.)

EXAMINATION – ACTIVITY LIMITATION MEASURES: Clinicians should utilize easily reproducible activity limitation and participation restriction measures associated with their patient's shoulder pain to assess the changes in the patient's level of shoulder function over the episode of care. (Recommendation based on expert opinion.)

EXAMINATION – PHYSICAL IMPAIRMENT MEASURES: Clinicians should measure pain, active shoulder range of motion (ROM), and passive shoulder ROM to assess the key impairments of body function and body structures in patients with adhesive capsulitis. Glenohumeral joint accessory motion may be assessed to determine translational glide loss. (Recommendation based on theoretical/foundational evidence.)

INTERVENTION – CORTICOSTEROID INJECTIONS: Intra-articular corticosteroid injections combined with shoulder mobility and stretching exercises are more effective in providing short-term (4-6 weeks) pain relief and improved function compared to shoulder mobility and stretching exercises alone. (Recommendation based on strong evidence.)

INTERVENTION – PATIENT EDUCATION: Clinicians should utilize patient education that (1) describes the natural course of the disease, (2) promotes activity modification to encourage functional, pain-free ROM, and (3) matches the intensity of stretching to the patient's current level of irritability. (Recommendation based on moderate evidence.)

INTERVENTION – MODALITIES: Clinicians may utilize short-wave diathermy, ultrasound, or electrical stimulation combined with mobility and stretching exercises to reduce pain and improve shoulder ROM in patients with adhesive capsulitis. (Recommendation based on weak evidence.)

INTERVENTION – JOINT MOBILIZATION: Clinicians may utilize joint mobilization procedures primarily directed to the glenohumeral joint to reduce pain and increase motion and function in patients with adhesive capsulitis. (Recommendation based on weak evidence.)

Recommendations *(continued)*

INTERVENTION – TRANSLATIONAL MANIPULATION: Clinicians may utilize translational manipulation under anesthesia directed to the glenohumeral joint in patients with adhesive capsulitis who are not responding to conservative interventions. (Recommendation based on weak evidence.)

INTERVENTION – STRETCHING EXERCISES: Clinicians should instruct patients with adhesive capsulitis in stretching exercises. The intensity of the exercises should be determined by the patient's tissue irritability level. (Recommendation based on moderate evidence.)

Introduction

AIM OF THE GUIDELINES

The Orthopaedic Section of the American Physical Therapy Association (APTA) has an ongoing effort to create evidence-based practice guidelines for orthopaedic physical therapy management of patients with musculoskeletal impairments described in the World Health Organization's International Classification of Functioning, Disability and Health (ICF).¹³⁷

The purposes of these clinical guidelines are to:

- Describe evidence-based physical therapy practice, including diagnosis, prognosis, intervention, and assessment of outcome, for musculoskeletal disorders commonly managed by orthopaedic physical therapists
- Classify and define common musculoskeletal conditions using the World Health Organization's terminology related to impairments of body function and body structure, activity limitations, and participation restrictions
- Identify interventions supported by current best evidence to address impairments of body function and structure, activity limitations, and participation restrictions associated with common musculoskeletal conditions
- Identify appropriate outcome measures to assess changes resulting from physical therapy interventions in body function and structure as well as in activity and participation of the individual
- Provide a description to policy makers, using internation-

ally accepted terminology, of the practice of orthopaedic physical therapists

- Provide information for payers and claims reviewers regarding the practice of orthopaedic physical therapy for common musculoskeletal conditions
- Create a reference publication for orthopaedic physical therapy clinicians, academic instructors, clinical instructors, students, interns, residents, and fellows regarding the best current practice of orthopaedic physical therapy

STATEMENT OF INTENT

These guidelines are not intended to be construed or to serve as a standard of medical care. Standards of care are determined on the basis of all clinical data available for an individual patient and are subject to change as scientific knowledge and technology advance and patterns of care evolve. These parameters of practice should be considered guidelines only. Adherence to them will not ensure a successful outcome in every patient, nor should they be construed as including all proper methods of care or excluding other acceptable methods of care aimed at the same results. The ultimate judgment regarding a particular clinical procedure or treatment plan must be made in light of the clinical data presented by the patient and the diagnostic and treatment options available. However, we suggest that significant departures from accepted guidelines should be documented in the patient's medical records at the time the relevant clinical decision is made.

Methods

Content experts were appointed by the Orthopaedic Section, APTA as developers and authors of clinical practice guidelines for musculoskeletal conditions of the shoulder that are commonly treated by physical therapists. These content experts were given the task of identifying impairments of body function and structure, activity limitations, and participation restrictions, described using ICF terminology, that could (1) categorize patients into mutually exclusive impairment patterns upon which to base intervention strategies, and (2) serve as measures of changes in function over the course of an episode of care. The second task given to the content experts was to describe interventions and supporting evidence for specific subsets of patients based on the previously chosen patient categories. It was also acknowledged by the Orthopaedic Section, APTA content experts that only performing a systematic search and review of the evidence related to diagnostic categories based on International Statistical Classification of Diseases and Related Health Problems (ICD)¹³⁶ terminology would not be sufficient for these ICF-based clinical practice guidelines, as most of the evidence associated with changes in levels of impairment or function in homogeneous populations is not readily searchable using the ICD terminology. Thus, the authors of these guidelines independently performed a systematic search of MEDLINE, CINAHL, and the Cochrane Database of Systematic Reviews (1966 through September 2011) for any relevant articles related to classification, examination, and intervention for musculoskeletal conditions related to classification, outcome measures, and intervention strategies for shoulder adhesive capsulitis and frozen shoulder. Additionally, when relevant articles were identified, their reference lists were hand searched in an attempt to identify other relevant articles. These guidelines were issued in 2013, based on publications in the scientific literature prior to September 2011. These guidelines will be considered for review in 2017, or sooner if new evidence becomes available. Any updates to these guidelines in the interim period will be noted on the Orthopaedic Section of the APTA website: www.orthopt.org.

LEVELS OF EVIDENCE

Individual clinical research articles were graded according to criteria described by the Centre for Evidence-Based Medicine, Oxford, UK (<http://www.cebm.net>) for diagnostic, prospective, and therapeutic studies.¹⁰⁰ An abbreviated version of the grading system is provided as follows.

I	Evidence obtained from high-quality diagnostic studies, prospective studies, or randomized controlled trials
II	Evidence obtained from lesser-quality diagnostic studies, prospective studies, or randomized controlled trials (eg, weaker diagnostic criteria and reference standards, improper randomization, no blinding, less than 80% follow-up)
III	Case-controlled studies or retrospective studies
IV	Case series
V	Expert opinion

GRADES OF EVIDENCE

The overall strength of the evidence supporting recommendations made in these guidelines was graded according to guidelines described by Guyatt et al,⁴⁸ as modified by MacDermid et al⁷³ and adopted by the coordinator and reviewers of this project. In this modified system, the typical A, B, C, and D grades of evidence have been modified to include the role of consensus expert opinion and basic science research to demonstrate biological or biomechanical plausibility.

GRADES OF RECOMMENDATION BASED ON		STRENGTH OF EVIDENCE
A	Strong evidence	A preponderance of level I and/or level II studies support the recommendation. This must include at least 1 level I study
B	Moderate evidence	A single high-quality randomized controlled trial or a preponderance of level II studies support the recommendation
C	Weak evidence	A single level II study or a preponderance of level III and IV studies, including statements of consensus by content experts, support the recommendation
D	Conflicting evidence	Higher-quality studies conducted on this topic disagree with respect to their conclusions. The recommendation is based on these conflicting studies
E	Theoretical/foundational evidence	A preponderance of evidence from animal or cadaver studies, from conceptual models/principles, or from basic science/bench research supports this conclusion
F	Expert opinion	Best practice based on the clinical experience of the guidelines development team

Methods *(continued)*

REVIEW PROCESS

The Orthopaedic Section, APTA also selected consultants from the following areas to serve as reviewers of the early drafts of these clinical practice guidelines:

- Claims review
- Coding
- Epidemiology
- Medical practice guidelines
- Orthopaedic physical therapy residency education
- Orthopaedic physical therapy clinical practice
- Orthopaedic surgery
- Rheumatology
- Physical therapy academic education
- Sports physical therapy/rehabilitation clinical practice
- Sports physical therapy residency education

Comments from these reviewers were utilized by the authors to edit these clinical practice guidelines prior to submitting them for publication to the *Journal of Orthopaedic & Sports Physical Therapy*.

CLASSIFICATION

The terms *adhesive capsulitis*, *frozen shoulder*, and *periarthritis* have been used for patients with shoulder pain and mobility deficits. Adhesive capsulitis will be used in these guidelines to describe both primary idiopathic adhesive capsulitis and secondary adhesive capsulitis related to systemic disease, such as diabetes mellitus and thyroid disorders, as well as extrinsic or intrinsic factors, including cerebral vas-

cular accident, proximal humeral fracture, causative rotator cuff, or labral pathology. The term *adhesive capsulitis* is used, rather than *frozen shoulder*, because it is the term used in the ICD.

The ICD-10 code associated with **adhesive capsulitis** is **M75.0**. The corresponding ICD-9-CM code, commonly used in the United States, is **726.0**.

The primary ICF body function codes associated with shoulder pain and mobility deficits/adhesive capsulitis are **b28014 pain in the upper limb**, **b28016 pain in joints**, and **b7100 mobility of a single joint**. The primary ICF body structure codes associated with adhesive capsulitis are **s7201 joints of shoulder region** and **s7203 ligaments and fasciae of shoulder region**.

The primary ICF activities and participation codes associated with adhesive capsulitis are **d4150 maintaining a lying position**, **d5400 putting on clothes**, **d5401 taking off clothes**, and **d4452 reaching**. The secondary ICF activities and participation codes associated with adhesive capsulitis are **d2303 completing the daily routine**, **d4300 lifting**, **d4302 carrying in the arms**, **d4454 throwing**, **d4551 climbing**, **d4554 swimming**, **d5100 washing body parts**, **d5101 washing whole body**, **d5202 caring for hair**, **d6201 gathering daily necessities**, **d6402 cleaning living area**, **d6501 maintaining dwelling and furnishings**, **d6600 assisting others with self-care**, and **d9201 sports**.

CLINICAL GUIDELINES

Impairment/Function-Based Diagnosis

PREVALENCE

The prevalence of shoulder pain has been reported to be between 2.4% and 26%.^{25,69} Primary adhesive capsulitis is reported to affect 2% to 5.3% of the general population.^{5,17,71,97} The prevalence of secondary adhesive capsulitis related to diabetes mellitus and thyroid disease is reported to be between 4.3% and 38%.^{5,7,17,71,97} Milgrom et al⁷⁷ compared 126 patients (76 women; mean \pm SD age, 55.0 \pm 8.4 years; 50 men; mean \pm SD age, 54.7 \pm 8.7 years) with idiopathic adhesive capsulitis to prevalence data and found a significantly higher prevalence of diabetes among both women (23.7% versus 4.7%) and men (38.0% versus 6.5%) with adhesive capsulitis as compared to the age-matched population. The type of diabetes, type 1 or 2, was not identified. A significantly higher prevalence of hypothyroidism among women (21.1% versus 7.9%) with idiopathic adhesive capsulitis was found compared to the age-matched regional population.⁷⁷

PATHOANATOMICAL FEATURES

The glenohumeral joint is a synovial joint containing a synovial membrane lining the interior joint capsule and encasing the long head of the biceps tendon into the biceps groove. The glenohumeral capsule, coracohumeral ligament, and glenohumeral ligaments (superior, middle, and inferior) comprise the capsuloligamentous complex. This complex surrounds the glenohumeral joint inserting onto the humerus (superior to the lesser tuberosity and surgical and anatomic necks), from the coracoid and glenoid rim via the labrum and glenoid neck. The capsuloligamentous complex and rotator cuff tendons create an intimate static and dynamic constraining sleeve around the glenohumeral joint.^{28,99}

II Cadaver studies demonstrate the restricting influence of the subscapularis and selected capsuloligamentous complex portions.^{95,125} The proximal portion of the capsuloligamentous complex and the subscapularis were found to limit external rotation when the glenohumeral joint was positioned up to 45° of abduction. Turkel et al¹²⁵ found that the subscapularis limited external rotation the most with the arm at 0° of abduction. It has been suggested that a greater loss of external rotation at 45° versus 90° of abduction indicates subscapularis restriction.⁴⁴

II The rotator cuff interval forms a triangular-shaped tissue bridge between the anterior supraspinatus tendon edge and the upper subscapularis border, with the apex located on the biceps sulcus lateral ridge at the margin of the transverse humeral ligament.¹⁰² The rotator cuff interval is primarily composed of the superior glenohumeral ligament and the coracohumeral ligament.^{29,36,63,103} Recently, the anterosuperior capsule was found to have not only an anterior limb but also a posterior limb containing the previously unrecognized posterolateral glenohumeral ligament.¹⁰³

IV Adhesive capsulitis is marked by the presence of multiregional synovitis, consistent with inflammation,^{50,83,84,88,133} yet focal vascularity and synovial angiogenesis (increased capillary growth) rather than synovitis are described by others.^{20,55,134,135} Accompanying angiogenesis, there is evidence of new nerve growth in the capsuloligamentous complex of patients with adhesive capsulitis, which may explain the heightened pain response.⁴⁹ Regardless of the synovial pathology being angiogenesis or synovitis, significant pain can result at rest or with motion.

IV Significant capsuloligamentous complex fibrosis and contracture are consistently observed upon open or arthroscopic shoulder surgery and histologic examination. The entire capsuloligamentous complex can become fibrotic, but the rotator cuff interval and specifically the capsuloligamentous complex are predominantly involved.^{55,82,83,92,94,96,126,127,134} The rotator cuff interval is part of the anterosuperior complex, which functions as a superior hammock. With the arm at the side, the anterior limb restricts external rotation while the posterior limb restricts internal rotation.^{51,103} Coracohumeral ligament release in patients with adhesive capsulitis resulted in a dramatic increase in shoulder external rotation motion.^{50,82,92,94,96} Others have noted significant subacromial scarring,^{55,85} loss of the subscapular recess,^{71,86} inflammation of the long head of the biceps tendon and its synovial sheath,¹³³ and musculotendinous contracture.⁸⁵

E Clinicians should assess for impairments in the capsuloligamentous complex and musculotendinous structures surrounding the shoulder complex

when a patient presents with shoulder pain and mobility deficits (adhesive capsulitis). The loss of passive motion in multiple planes, particularly external rotation with the arm at the side and in varying degrees of shoulder abduction, is a significant finding that can be used to guide treatment planning.

RISK FACTORS

III Although the etiology of adhesive capsulitis has not been identified, there are a number of associated factors. Recent evidence implicates elevated serum cytokine levels as causing or resulting in a sustained intense and protracted inflammatory/fibrotic response affecting the synovial lining and capsuloligamentous complex in patients with adhesive capsulitis.^{21,54,113} To date, the relationship between cytokines and the causative factor, whether it is insidious or related to minor trauma, is unknown.

III Individuals with type 1 or 2 diabetes mellitus have a greater propensity of developing adhesive capsulitis.^{7,20,77,78,97} Patients with Dupuytren's disease or type 1 diabetes mellitus for 10 or more years have a greater incidence of primary adhesive capsulitis.^{5,7,20}

II Milgrom et al,⁷⁷ in a prospective study, identified risk factors associated with idiopathic adhesive capsulitis by comparing the prevalence of diabetes in new cases (n = 126) to age-matched controls over a 2.5-year period. Of the 126 new cases, 29.3% had diabetes mellitus. Patients with adhesive capsulitis had a higher rate of diabetes mellitus compared to an age-matched population, as indicated by the risk ratios of 5.9 (95% confidence interval [CI]: 4.1, 8.4) in men and 5.0 (95% CI: 3.3, 7.5) in women. Balci et al⁷ evaluated patients with type 2 diabetes mellitus (n = 297; 60% female) to determine the presence of adhesive capsulitis and other conditions. They found that 29% (men, 33.6%; women, 25.9%) had adhesive capsulitis, as defined by having at least 1 month of shoulder pain, an inability to lie on the affected side, and restricted active and passive shoulder motion in 3 or more planes. Additionally, they found a significant relationship between adhesive capsulitis and Dupuytren's contracture. Adhesive capsulitis was associated with age (mean ± SD, 59.23 ± 8.24 years) and the duration of diabetes. Aydeniz et al⁵ compared 102 patients (mean ± SD age, 58.0 ± 9.1 years) with type 2 diabetes mellitus to an age- and sex-matched control group and found that 14.7% had adhesive capsulitis, compared to 3.9% of the controls. The incidence of Dupuytren's contracture was higher in the diabetic group (12.7%) versus the control group (3.9%). There were significant associations between age, diabetes duration, and musculoskeletal complications (ie, Dupuytren's contracture, trigger finger).

II Thyroid disease is a risk factor associated with adhesive capsulitis. Milgrom et al⁷⁷ reported that 13.4% of patients with adhesive capsulitis had thyroid dysfunction. The majority of the patients with thyroid disease who developed adhesive capsulitis were women (16 of 17). Milgrom et al⁷⁷ reported an increased prevalence of thyroid dysfunction in patients with adhesive capsulitis compared to an age-matched regional population, as demonstrated by risk ratios of 7.3 (95% CI: 4.8, 11.1) in women and 2.6 (95% CI: 0.4, 17.0) in men.

II Cakir et al²² performed physical examinations on 137 patients (111 females, 26 males) with hyperthyroidism or hypothyroidism. The prevalence of adhesive capsulitis was 10.9%. In addition, both Dupuytren's contracture (8.8%) and carpal tunnel syndrome (9.5%) were associated with thyroid disease.²²

II Age can be considered a risk factor because adhesive capsulitis more commonly occurs in individuals between 40 and 65 years of age, with the reported peak incidence occurring, on average, between 51 and 55.^{71,84,87,89,97} Females appear to be affected more commonly than males.^{5,12,50,71,77,120} However, a greater proportion of males (33.6%) than females (25.9%) had adhesive capsulitis in an identified group of patients with diabetes mellitus.⁷ Having adhesive capsulitis on 1 side places an individual at risk (5%-34%) for opposite-arm involvement in the future, and adhesive capsulitis can occur bilaterally simultaneously up to 14% of the time.^{18,45,71,119}

IV Other associated risk factors include prolonged immobilization, myocardial infarction, trauma, and autoimmune disease.^{16,18,104,111,140}

B Clinicians should recognize that (1) patients with diabetes mellitus and thyroid disease are at risk for developing adhesive capsulitis, and (2) adhesive capsulitis is more prevalent in individuals who are 40 to 65 years of age, female, and have had a previous episode of adhesive capsulitis in the contralateral arm.

CLINICAL COURSE

Four stages of adhesive capsulitis, reflecting a continuum, have been described.^{50,83,89} Stage 1 may last up to 3 months, and during this stage patients describe sharp pain at end ranges of motion, achy pain at rest, and sleep disturbance. During this stage, arthroscopic examination reveals diffuse synovial reaction without adhesions or contracture.^{50,83,89} Subacromial shoulder impingement is often the suspected clinical diagnosis early in this stage because there are minimal to no ROM restrictions.^{83,89} Early loss of external rota-

tion motion with an intact rotator cuff is a hallmark sign of adhesive capsulitis and may be seen in this stage.^{37,83} Stage 2, known as the “painful” or “freezing” stage, presents with a gradual loss of motion in all directions due to pain and can last from 3 to 9 months. Arthroscopic examination reveals aggressive synovitis/angiogenesis and some loss of motion under anesthesia.^{50,83,89} Stage 3, known as the “frozen” stage, is characterized by pain and loss of motion and lasts from 9 to 15 months. In stage 3, the synovitis/angiogenesis lessens but the progressive capsuloligamentous fibrosis results in loss of the axillary fold and ROM when tested under anesthesia.^{50,83,89} Stage 4, known as the “thawing” stage, is characterized by pain that begins to resolve, but significant stiffness persists from 15 to 24 months after onsets of symptoms.^{50,89,90} This stage often progresses to pain resolution, but motion restrictions may persist that are unchanged even when examined under anesthesia. Arthroscopy reveals capsuloligamentous complex fibrosis and receding synovial involvement.^{83,89} Although adhesive capsulitis was initially considered a 12- to 18-month self-limited process, mild symptoms may persist for years, depending on the extent of fibroplasia and subsequent resorption.^{11,19,30,31,45,119} Patients with diabetes mellitus may have a protracted recovery and worse outcomes.⁴⁵

II Binder et al¹¹ performed a prospective study (n = 40) on patients with adhesive capsulitis. Patients were classified as having adhesive capsulitis if they had shoulder pain for at least 1 month, sleep disturbance due to pain, an inability to lie on the affected shoulder, restriction in all active and passive shoulder movements, and at least a 50% reduction in external rotation motion. The investigators did not state whether the 50% loss of external rotation was compared to established norms or compared to the uninvolved extremity. The authors noted that at 6 months and at a minimum of 3 years after the diagnosis, 90% and 40% of the patients, respectively, had not regained normal ROM when compared to an age- and sex-matched control group. They concluded that at a long-term follow-up (mean, 44 months), measurable mobility deficits persisted but patients had little functional deficits.

IV Griggs et al⁴⁵ assessed 75 patients who fit the criteria for stage 2 adhesive capsulitis. In addition, the patients had a history of no or only trivial shoulder trauma; loss of active and passive shoulder ROM (more than a 50% loss of external rotation), especially with the shoulder abducted at 90°; pain at the extremes of all shoulder motions; globally limited glenohumeral joint translation; and normal glenohumeral joint radiographic findings. The investigators found that 27% of these 75 patients continued to have mild pain with activity and that all patients demonstrated mobility deficits compared to their uninvolved side at an average of 22 months following the onset of adhesive

capsulitis. The vast majority of patients (90%) were satisfied with their outcome. Less than half (40%) reported residual shoulder disability, with an average \pm SD score of 9.7 ± 13.6 points on the DASH questionnaire (range of score from 0 to 100, with 0 representing no disability). However, ROM did not correlate with patient-rated outcome scores on the simple shoulder test (SST) and the DASH, but pain with activity rating did correlate with functional loss. Diabetes mellitus and male gender were related to worse ROM outcomes. Seven percent of the patients were eventually treated with manipulation under anesthesia and/or capsular release. A history of prior rehabilitation and workers' compensation or pending litigation was associated with being treated with manipulation and/or capsular release.

IV Shaffer et al¹¹⁹ retrospectively examined patients with adhesive capsulitis (n = 62) who were treated conservatively. The criteria for inclusion were a minimum of 1 month of shoulder pain and stiffness for which no other cause could be identified, documented restriction of passive glenohumeral and scapulothoracic motion of 100° of abduction or less, and less than 50% of external rotation when compared to the contralateral shoulder. In an average of 6 months, pain resolved and motion returned to normal or within 10° to 15° of normal. At an average of a 7-year follow-up, 89% of patients had no functional deficits, but 50% continued to report mild pain or stiffness. However, ROM loss did not correlate with functional deficits.

IV Levine et al⁶⁸ performed a retrospective review of 98 patients (105 shoulders) with the diagnosis of idiopathic adhesive capsulitis. The criteria for inclusion were diagnosis of adhesive capsulitis and treatment by 1 of 4 shoulder surgeons. The Medical Outcomes Study 36-Item Short-Form Health Survey (SF-36), the ASES, and the SST were used as patient-rated outcome measures, and ROM as the impairment measure. The average duration of treatment was 4.7 months, and 18.1% of the patients had diabetes mellitus. Symptoms resolved in 89.5% of the patients who were managed with physical therapy, nonsteroidal anti-inflammatory drugs, intra-articular corticosteroid injections, or some combination of the 3. No difference in recovery was seen between patients with diabetes mellitus and those without diabetes. Ten percent of the patients required operative management, with this group demonstrating greater loss of elevation and external rotation ROM both initially and preoperatively. Therefore, those who required surgery had less shoulder ROM at the time of diagnosis, and their ROM continued to decrease during the course of nonoperative treatment.

C Clinicians should recognize that adhesive capsulitis occurs as a continuum of pathology characterized by a staged progression of pain and mobility defi-

cits and that, at 12 to 18 months, mild to moderate mobility deficits and pain may persist, though many patients report minimal to no disability.

DIAGNOSIS/CLASSIFICATION

Diagnosis

V The diagnosis of shoulder pain and mobility deficits associated with primary or secondary adhesive capsulitis is determined from the history and physical examination. Patients typically present with a gradual and progressive onset of pain, likely sleep-disturbing night pain and pain at end ranges of movements. Patients also present with painful and restricted active and passive ROM in both elevation and rotation that occurs for at least 1 month and has either reached a plateau or worsened.¹¹ Functional activities such as reaching overhead, behind the back, or out to the side become increasingly difficult due to pain and/or stiffness.

III The primary purpose for diagnosis/classification of shoulder pain is to direct intervention and inform prognosis. Traditionally, a patho-anatomic model has been used to identify the symptomatic tissue(s) and distinguish among various pathologies. A proposed classification scheme¹⁴⁰ suggests that primary frozen shoulder and idiopathic adhesive capsulitis are considered identical and not associated with a systemic condition or history of injury. Furthermore, secondary adhesive capsulitis or frozen shoulder is defined by a relationship between a disease or pathology with 3 subcategories: systemic, extrinsic, and intrinsic. Systemic secondary adhesive capsulitis includes those patients with a history of diabetes mellitus and thyroid disease. Extrinsic secondary adhesive capsulitis includes patients whose pathology is not directly related to the shoulder, yet it results in a painful and stiff shoulder, such as with a cerebral vascular accident, intrathoracic conditions (eg, myocardial infarction and chronic obstructive pulmonary disease), intra-abdominal conditions (eg, chronic liver disease), cervical disc disease, distal extremity fracture, or self-imposed immobilization. Intrinsic secondary adhesive capsulitis describes patients with a known pathology of the glenohumeral joint soft tissues or structures, such as rotator cuff tendinopathy, biceps tendinopathy, calcific tendinitis, acromioclavicular or glenohumeral joint arthropathy, or proximal humeral or scapular fracture.¹⁴⁰ Loss of shoulder ROM and pain that is associated with postoperative stiffness should not be considered adhesive capsulitis. These categorizations present a theoretical framework; however, there is a lack of evidence with regard to their ability to drive treatment decision making and to prognosticate outcome.

Classification

V Patients with adhesive capsulitis present with a number of impairments, but most characteristically have a global loss of both active and passive shoulder ROM.⁵⁰ Generally, ROM loss of greater than 25% in at least 2 planes and passive external rotation loss that is greater than 50% of the uninvolved shoulder or less than 30° of external rotation have been used to define adhesive capsulitis.^{12,19,20,23,37,45,61,82,85,106,110,119,131,132} The capsular pattern described by Cyriax,³⁷ where external rotation motion loss is proportionally greater than loss of abduction, which is more limited than internal rotation, is not consistently found when objective measurements are taken. Rundquist et al¹¹⁶ found varying patterns of restriction in patients with adhesive capsulitis, but the most common pattern was a loss of external rotation with the arm at the side followed by a loss of abduction and internal rotation. A consistent finding was a greater loss of internal rotation versus external rotation when the arm was positioned as close as possible to 90° of frontal plane abduction.¹¹⁶ Cyriax³⁷ described patients with adhesive capsulitis as having normal strength and painless responses to resisted tests. However, others have described patients with adhesive capsulitis as having reduced shoulder muscle strength with isometric testing,^{58,66,121} specifically weakness of the internal rotators,^{58,66} elevators,^{66,121} and external rotators. Special tests, such as impingement signs and the Jobe test, are not helpful in differentiating adhesive capsulitis from rotator cuff tendinopathy, as they reproduce pain because they involve end-range positioning of the painful and stiff capsuloligamentous complex.

V A medical diagnosis of adhesive capsulitis may be helpful in describing the tissue pathology, but it does not aid in treatment decision making for rehabilitation. An impairment-based classification is necessary to guide rehabilitation; however, there is no published classification system. Thus, the current guidelines include a proposed model for diagnosis, examination, and treatment planning for patients with shoulder pain and mobility deficits, using the following components:

- Evaluation/Intervention Component 1: medical screening
- Evaluation/Intervention Component 2: differential evaluation of clinical findings suggestive of musculoskeletal impairments of body functioning (ICF) and the associated tissue pathology/disease (ICD)
- Evaluation/Intervention Component 3: diagnosis of tissue irritability level
- Evaluation/Intervention Component 4: intervention strategies for shoulder pain and mobility deficits

This model is depicted in the **FIGURE**.

Evaluation/Intervention Component 1: medical screening

Appropriate for physical therapy evaluation and intervention

versus

Appropriate for physical therapy evaluation and intervention along with consultation with another healthcare provider

versus

Not appropriate for physical therapy evaluation and intervention

Evaluation/Intervention Component 2: differential evaluation of clinical findings suggestive of musculoskeletal impairments of body functioning (ICF) and the associated tissue pathology/disease (ICD)

Consultation with appropriate healthcare provider

Diagnostic Classification Criteria

Shoulder pain and mobility deficits/adhesive capsulitis

Rule in if:

- Patient's age is between 40 and 65 years
- Patient reports a gradual onset and progressive worsening of pain and stiffness
- Pain and stiffness limit sleeping, grooming, dressing, and reaching activities
- Glenohumeral passive range of motion (ROM) is limited in multiple directions, with external rotation the most limited, more particularly in adduction
- Glenohumeral external or internal rotation ROM decreases as the humerus is abducted from 45° toward 90°
- Passive motions into the end ranges of glenohumeral motions reproduce the patient's reported shoulder pain
- Joint glides/accessory motions are restricted in all directions

Rule out if:

- Passive ROM is normal
- Radiographic evidence of glenohumeral arthritis is present
- Passive glenohumeral external or internal rotation ROM increases as the humerus is abducted from 45° toward 90° and the reported shoulder pain is reproduced with palpatory provocation of the subscapularis myofascia
- Upper-limb nerve tension testing reproduces the reported symptoms and shoulder pain can be increased or decreased with altering nerve tension positions
- Shoulder pain is reproduced with palpatory provocation of the relevant peripheral nerve entrapment site

Shoulder stability and movement coordination impairments/dislocation of shoulder joint, or sprain and strain of shoulder joint

Rule in if:

- Patient's age is less than 40 years
- History of shoulder dislocation
- Excessive glenohumeral accessory motions in multiple directions
- Apprehension at end ranges of flexion, horizontal abduction, and/or external rotation

Rule out if:

- No history of dislocation
- Presence of global glenohumeral motion limitations
- No apprehension with end-range shoulder active or passive motions

Shoulder pain and muscle power deficits/rotator cuff syndrome

Rule in if:

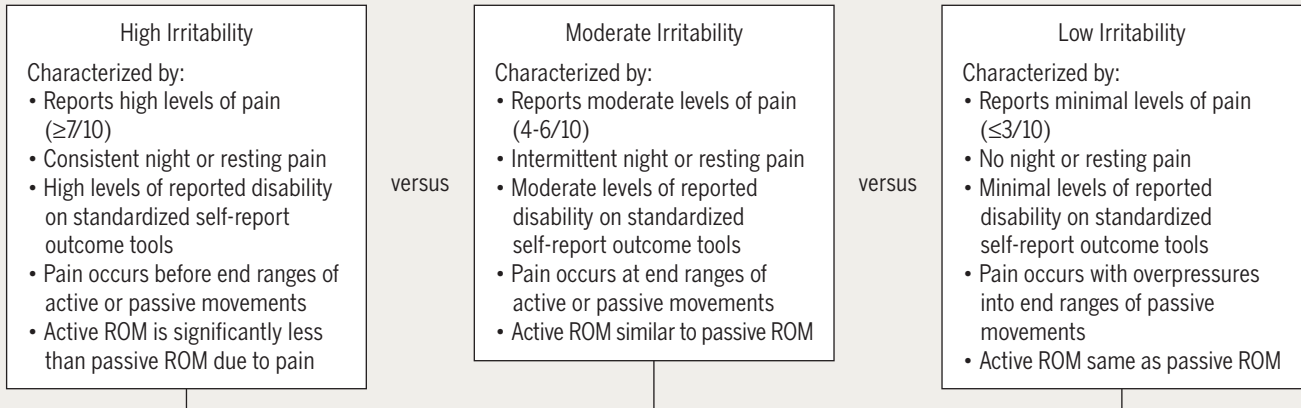
- Symptoms developed from, or worsen with, repetitive overhead activities or from an acute strain such as a fall onto the shoulder
- Midrange (about 90°) catching sensation/arc of pain with active elevation
- Manual resistive tests to the rotator cuff muscles, performed in midranges of shoulder flexion and abduction, reproduce the patient's reported shoulder pain
- Rotator cuff muscle weakness

Rule out if:

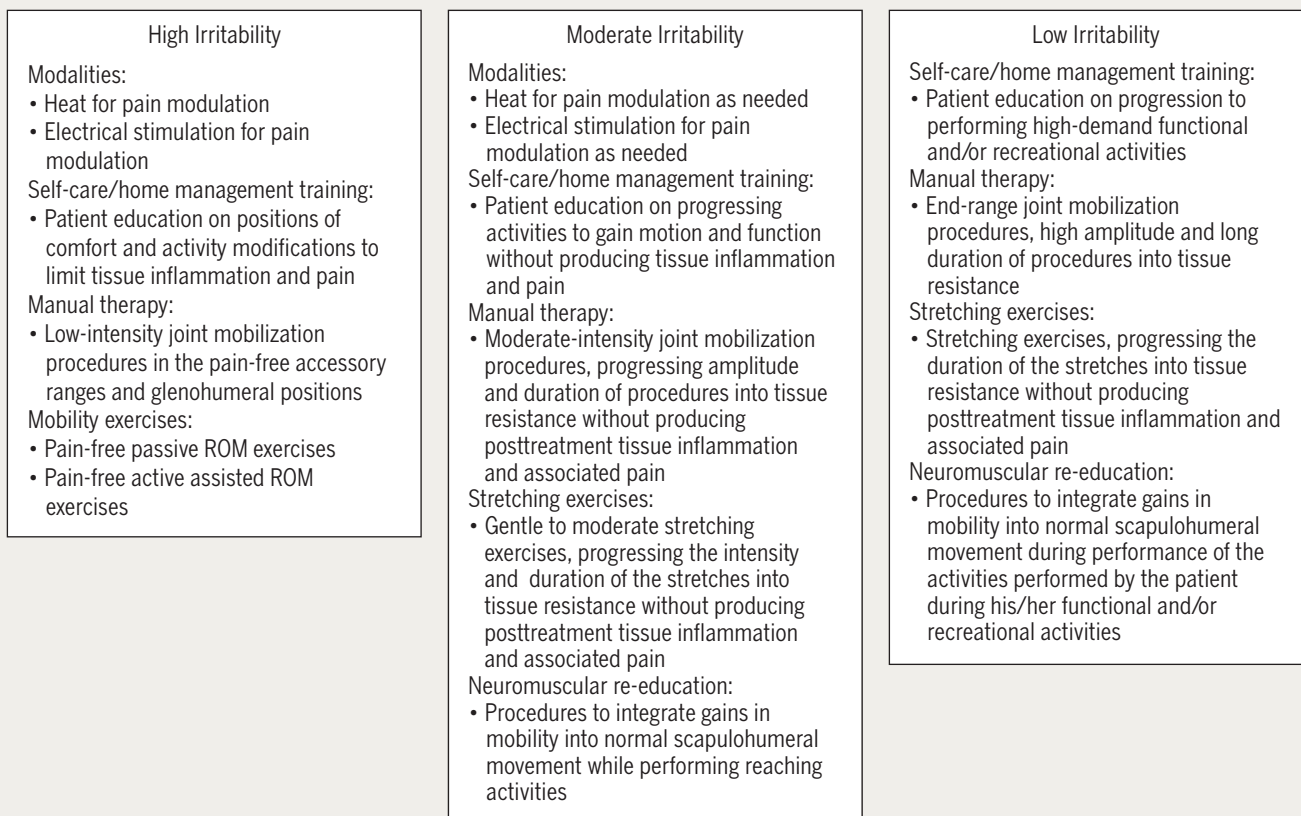
- Resistive tests are pain free
- Supraspinatus, infraspinatus, and biceps brachii have normal strength
- Significant loss of passive motion

Figure continued on page A11

Evaluation/Intervention Component 3: diagnosis of tissue irritability level



Evaluation/Intervention Component 4: intervention strategies for shoulder pain and mobility deficits



Component 1

Medical screening incorporates the findings of the history and physical examination to determine whether the patient's

symptoms originate from a more serious pathology, such as a tumor or infection, rather than from a common shoulder musculoskeletal disorder.^{80,139} In addition to serious medi-

cal conditions, clinicians should screen for the presence of psychosocial issues that may affect prognostication and treatment decision making for rehabilitation. For example, elevated scores on the Tampa Scale of Kinesiophobia or the Fear-Avoidance Beliefs Questionnaire have been associated with a longer recovery, chronic symptoms, and work loss in patients with shoulder pain.^{42,59,79} Accordingly, identifying cognitive behavioral tendencies during the patient's evaluation can direct the therapist to employ specific patient education strategies to optimize patient outcomes to physical therapy interventions and potentially provide indications for referring the patient for consultation with another medical or mental health practitioner.¹⁰

Component 2

Differential evaluation of musculoskeletal clinical findings is used to determine the most relevant physical impairments associated with the patient's reported activity limitations and medical diagnosis. Clusters of these clinical findings, which commonly coexist in patients, are described as impairment patterns in the physical therapy literature¹ and are labeled according to the key impairment(s) of body function associated with that cluster. These impairment patterns are useful in driving the interventions, which focus on normalizing the key impairments of body function, which in turn improves the movement and function of the patient and lessens or alleviates the activity limitations commonly reported by the patients who meet the diagnostic criteria of that specific pattern. Key clinical findings to rule in and rule out the common impairment patterns, and their associated medical conditions, are shown in the **FIGURE**. Impairment-based classification is critical for matching the intervention strategy that is most likely to provide the optimal outcome for a patient's clinical findings. However, it is important for clinicians to understand that patients with shoulder pain often fit more than 1 impairment pattern and that the most relevant impairments of body function and the associated intervention strategies often change during the patient's episode of care. Thus, continual re-evaluation of the patient's response to treatment and the patient's emerging clinical findings is important for providing the optimal interventions throughout the patient's episode of care.

Component 3

Diagnosis of tissue irritability is important for guiding the clinical decisions regarding treatment frequency, intensity, duration, and type, with the goal of matching the optimal dosage of treatment to the status of the tissue being treated. *Irritability* is a term used by rehabilitation practitioners to reflect the tissue's ability to handle physical stress,⁸¹ and is presumably related to physical status and the extent of inflammatory activity that is present. Three levels of irritability

are operationally defined in the **FIGURE**. The primary clinical finding that determines the level of tissue irritability is the relation between pain and active and passive movements. Other clinical findings that characterize the level of tissue irritability are pain level, frequency of pain, and level of disability reported by the patient.

Component 4

Because irritability level often reflects the tissue's ability to accept physical stress, clinicians should match the most appropriate intervention strategies to the level of irritability.⁶⁰ Patients with a high level of tissue irritability are not ready for significant physical stress being applied to the affected tissues, and therefore the treatment should emphasize activity modification and appropriate modalities, medication, and manual therapy to relieve pain and inflammation. In addition, only low levels of glenohumeral exercises should be performed while encouraging motion at adjacent regions. Patients with a moderate level of irritability should be able to tolerate controlled physical stress in the form of progressive manual therapy, mild stretching, and strengthening activities. They should also be able to perform basic functional activities. In comparison, patients with low irritability should be able to tolerate progressive physical stress in the form of stretching, manual therapy, resistive exercise, and higher-demand physical activities.

F Clinicians should recognize that patients with adhesive capsulitis present with a gradual and progressive onset of pain and loss of active and passive shoulder motion in both elevation and rotation. Utilizing the evaluation and intervention components described in these guidelines will assist clinicians in medical screening, differential evaluation of common shoulder musculoskeletal disorders, diagnosing tissue irritability levels, and planning intervention strategies for patients with shoulder pain and mobility deficits.

DIFFERENTIAL DIAGNOSIS

In addition to the 3 most common shoulder conditions outlined in the Diagnosis/Classification section of these clinical guidelines—adhesive capsulitis; sprain and strain of shoulder joint/dislocation; and rotator cuff syndrome/tendinopathy of the supraspinatus, infraspinatus, and biceps brachii—the following conditions, using ICD-10 terminology,¹³⁶ should be considered in the differential diagnosis when a patient presents with shoulder pain:

- Acute calcific tendonitis/bursitis
- Arthrosis of the shoulder, primary
- Arthrosis of the shoulder, secondary
- Bursitis of the shoulder

- Cervicalgia
- Cervical disc disorders
- Cervicobrachial syndrome
- Contusion of shoulder and upper arm
- Diseases of the digestive system
- Fibromyalgia
- Fracture of clavicle
- Fracture of scapula
- Fracture of shaft of humerus
- Fracture of upper end of humerus
- Impingement syndrome of the shoulder
- Injury of blood vessels at shoulder and upper-arm level, including avascular necrosis
- Injury of muscle and tendon at shoulder and upper-arm level, including labral lesions
- Injury of nerves at shoulder and upper-arm level, including suprascapular nerve entrapment
- Juvenile rheumatoid arthritis
- Neoplasm
- Osteoarthritis of the acromioclavicular joint
- Osteoarthritis of the cervical spine
- Osteoarthritis of the glenohumeral joint
- Osteoporosis with pathological fracture
- Pain in thoracic spine
- Persistent somatoform pain disorder
- Psychological and behavioral factors associated with disorders or diseases
- Pyogenic arthritis
- Radiculopathy
- Rheumatoid arthritis
- Somatoform autonomic dysfunction
- Sprain and strain of acromioclavicular joint
- Sprain and strain of sternoclavicular joint

F Clinicians should consider diagnostic classifications other than adhesive capsulitis when the patient's reported activity limitations or impairments of body function and structure are not consistent with the Diagnosis/Classification section of these guidelines, or when the patient's symptoms are not resolving with interventions aimed at normalization of the patient's impairments of body function.

IMAGING

Diagnosing adhesive capsulitis is primarily determined by history and physical examination, but imaging studies can be used to rule out underlying pathology. Radiographs are typically normal with adhesive capsulitis but can identify osseous abnormalities, such as glenohumeral osteoarthritis. Arthrographic findings associated with adhesive capsulitis include a joint capsule capacity of less than 10 to 12 mL and variable filling of the axillary and subscapular recess.^{71,86,105}

Magnetic resonance imaging (MRI) may help with the differential diagnosis by identifying soft tissue and bony abnormalities.^{9,128} MRI has identified abnormalities of the capsule and rotator cuff interval in patients with adhesive capsulitis.^{33,41,75} Mengiardi et al⁷⁵ performed magnetic resonance arthrograms on 122 patients who were treated with arthroscopic capsular release and compared the findings with those of an age- and sex-matched control group; findings included a thickened coracohumeral ligament and joint capsule in the rotator cuff interval and a smaller axillary recess volume, but without axillary recess thickening. Using MRI, axillary recess thickening, joint volume reduction, rotator cuff interval thickening, and proliferative synovitis surrounding the coracohumeral ligament have been observed in patients with adhesive capsulitis.^{33,41}

A recent study⁶⁴ using ultrasonography with arthroscopic confirmation identified fibrovascular inflammatory soft tissue changes in the rotator cuff interval in 100% of 30 patients with adhesive capsulitis with symptoms less than 12 months. Homsí et al⁵² performed ultrasound examinations of the coracohumeral ligament on 306 individuals with painful shoulders, 121 asymptomatic shoulders, and 17 shoulders with arthrographic evidence of adhesive capsulitis. The average thickness of the coracohumeral ligament was 3 mm in the adhesive capsulitis group, 1.34 mm in the asymptomatic group, and 1.39 mm in the non-adhesive capsulitis painful-shoulder group. Coracohumeral ligament thickness was significantly greater ($P = .0001$) in the adhesive capsulitis group compared to the asymptomatic group and the non-adhesive capsulitis painful-shoulder group.

CLINICAL GUIDELINES

Examination

OUTCOME MEASURES

There are several outcome measures designed to assess patients with shoulder disorders. These tools can be classified as shoulder joint specific, shoulder disease specific, or upper limb specific. Over 30 tools have been published; however, not all have demonstrated acceptable measurement properties. The shoulder outcome tools that are most widely used and embraced by professional societies involved with the treatment of shoulder pain are the Constant score,³⁴ the DASH,⁵³ the SPADI,^{14,112} and the ASES.¹⁰⁷

The Constant score is the most widely used scale in Europe. It has 2 sections, a patient self-report section and a clinician-report section, and scores can range from 0 to 100, with 100 indicating maximum use of the shoulder. The self-report section contains a single pain question (15 points) and 4 questions assessing work, sport, sleep, and position of arm use (20 points), for a maximum total of 35 points. Measurement properties of the Constant score self-report section have been investigated.^{15,32,34} However, because there are only 4 items to assess patient-rated function, it is not clear if the Constant score items comprehensively represent the construct of shoulder use, and therefore this outcome measure is not recommended for use.

Two recent systematic reviews^{15,115} indicated that the ASES, DASH, SPADI, and SST have been the most studied shoulder outcome tools for psychometric properties. The ASES, DASH, and SPADI have demonstrated acceptable psychometric properties, whereas the SST has only limited or no evidence as to the error in the measure and clinically meaningful change. Therefore, the ASES, DASH, and SPADI are recommended for clinical use.^{15,115}

The ASES is a patient self-report scale that has a range of scores from 0 to 100, with 100 indicating maximum shoulder use, consisting of 50 points maximum for pain (1 question) and 50 points maximum for activities/participation questions (10 questions). Studies of the ASES indicate adequate measurement properties.^{15,35,62,76,115,122} The minimal detectable change (MDC), the change in scores that is considered greater than measurement error at the 90% confidence level, for the ASES has been reported to be 9.4 points, and the minimal clinically important difference has been reported to be 6.4 points.^{76,115}

The DASH is a 30-question patient self-report questionnaire. The scores range from 0 to 100, with 0 indicating no disability. The measurement properties of the DASH have been extensively investigated.^{2,8,15,43,47,53,72,118} The MDC has been reported to be between 6.6 and 12.2 points (weighted average, 10.5 points),^{8,43,118} and the minimal clinically important difference has been reported to be 10.2 points.^{115,118}

The SPADI¹¹² is a 13-item patient self-report tool with 2 domains, 5 pain items, and 8 items of disability. Each domain score is equally weighted for the total score. The total score ranges from 0 to 100, with 0 indicating no pain or difficulty. Studies of the SPADI have indicated adequate measurement properties.^{15,115} The MDC at the 90% confidence level has been reported to be 18.1,¹¹⁸ the MDC at the 95% confidence level has been reported to be 18.0,³ and the minimal clinically important difference has been reported to be 8.0⁹⁸ and 13.1¹¹⁵ points. Most recently, Staples et al¹²³ concluded that the SPADI had superior responsiveness when compared to the DASH in patients with adhesive capsulitis.

A

Clinicians should use validated functional outcome measures, such as the DASH, the ASES, or the SPADI. These should be utilized before and after interventions intended to alleviate the impairments of body function and structure, activity limitations, and participation restrictions associated with adhesive capsulitis.

ACTIVITY LIMITATIONS

Activity limitation measures have not been reported in the literature other than what is indicated for the patient self-report questionnaires. The following measures can help the clinician to assess changes in the patient's level of function over time:

- Pain during sleep
- Pain and difficulty with grooming and dressing activities
- Pain and difficulty with reaching activities: to the shoulder level, behind the back, and overhead

F

Clinicians should utilize easily reproducible activity limitation and participation restriction measures associated with their patients' shoulder pain to assess the changes in the patient's level of shoulder function over the episode of care.

PHYSICAL IMPAIRMENT MEASURES

Active and Passive Shoulder ROM

- ICF category: measurement of impairment of body function: mobility of a single joint
- Description: the amount of active or passive ROM of the glenohumeral joint as measured with a standard goniometer. Motion can be performed supine or in the upright position

Measurement Methods

Glenohumeral External Rotation in Adduction

To measure external rotation ROM with the shoulder adducted, the patient is positioned in supine with the upper arm comfortably by the side and the elbow flexed to 90°. The examiner passively externally rotates the glenohumeral joint until end range is reached. ROM is measured by placing the axis of the goniometer on the olecranon process. The stationary arm is aligned with the vertical position. The movable arm is aligned with the ulnar styloid process. Alternatively, the patient can be asked to actively externally rotate the shoulder to end range.

Glenohumeral External Rotation in Abduction

External rotation ROM may also be measured with the shoulder abducted to 45° or to 90° in the frontal plane (if the patient has the available abduction ROM). Placement of the axis and arms of the goniometer is similar to what is used with the adducted position.

Glenohumeral Internal Rotation in Abduction

Internal rotation ROM is measured with the patient positioned in supine, the shoulder abducted to 90°, and the elbow flexed to 90°. If glenohumeral abduction is less than 90°, a 45° abduction angle can be used. The examiner passively internally rotates the glenohumeral joint until end range is reached, ensuring that there is no scapular compensation. ROM is measured by placing the axis of the goniometer on the olecranon process. The stationary arm is aligned with the vertical position. The movable arm is aligned with the ulnar

styloid process. Alternatively, the patient can be asked to actively internally rotate the shoulder to end range.

Shoulder Flexion

To measure flexion ROM, the patient is positioned in supine with the arm comfortably by the side. The examiner passively flexes the shoulder until end range is reached (with no compensatory movements from the thorax and the lumbar spine). ROM is measured by placing the axis of the goniometer on the greater tuberosity. The stationary arm is aligned with the midline of the trunk. The movable arm is aligned with the lateral epicondyle. Alternatively, the patient can be asked to actively flex the shoulder to end range.

Shoulder Abduction

To measure abduction ROM, the patient is positioned in supine with the arm comfortably by the side. The examiner passively abducts the shoulder until end range is reached (shoulder must remain in the same plane). ROM is measured by placing the axis of the goniometer on the head of the humerus. The stationary arm is aligned parallel with the midline of the sternum. The movable arm is aligned with the midshaft of the humerus. Alternatively, the patient can be asked to actively abduct the shoulder to end range.

- Nature of variable: continuous
- Unit of measurement: degrees
- Measurement properties: measurements of shoulder ROM made with a standard goniometer demonstrate intraclass correlation coefficients ranging from 0.80 to 0.99.¹⁰⁸ Specifically, measures of passive shoulder external rotation ROM in patients with adhesive capsulitis have yielded intraclass correlation coefficients ranging from 0.98 to 0.99 (95% CI: 0.95, 0.99).⁵⁷

E Clinicians should measure pain, active shoulder ROM, and passive shoulder ROM to assess the key impairments of body function and body structures in patients with adhesive capsulitis. Glenohumeral joint accessory motion may be assessed to determine translational glide loss.

CLINICAL GUIDELINES

Interventions

Multiple interventions have been described for the treatment of adhesive capsulitis, and there is emerging evidence from high-quality randomized clinical trials regarding both short- and long-term efficacy of these interventions. Successful treatment does not require the patient to achieve full ROM. Instead, a successful outcome may be defined as a significant reduction of pain, improved function, and high levels of patient satisfaction.⁶⁰ These are often the short-term outcomes of conservative treatment. A successful long-term outcome could be defined as a continual improvement in shoulder motion and improved function over months as tissue remodels from thickened fibrotic tissue to more normal collagen tissue. In contrast, patients who present with shoulder pain and mobility deficits but have a relatively immediate significant return of motion and reduced symptoms after receiving corticosteroid injections, soft tissue or joint mobilization, and/or mobility or stretching exercises likely did not have adhesive capsulitis. Therefore, at times, the response to treatment helps determine the diagnosis.

CORTICOSTEROID INJECTIONS

Although corticosteroid injections are not directly part of the physical therapist's scope of practice, patients who have, or should consider receiving, glenohumeral joint intra-articular corticosteroid injections for adhesive capsulitis are commonly seen by physical therapists. Corticosteroids are administered to dampen the inflammatory response and reduce pain in patients with adhesive capsulitis. The following studies implicate pain and muscle guarding, as opposed to fibrosis or adhesions, as the initial barrier to joint motion because the results of all studies demonstrate significant improvements in motion immediately following steroid injections.

I Carette et al²³ performed a randomized controlled prospective study of 93 patients with adhesive capsulitis. Patients were classified as having adhesive capsulitis and included in this study if they had symptoms for more than 1 year, shoulder pain with limitation of both active and passive movements of the glenohumeral joint of more than 25% in at least 2 directions compared to the contralateral shoulder, and a total score of more than 30 on the SPADI. This study compared 4 different interventions. Group 1 was treated with a fluoroscopy-guided glenohumeral joint intra-articular corticosteroid injection. Group 2 received a combination of the fluoroscopy-guided glenohumeral joint intra-articular corticosteroid injection and

supervised physical therapy. Group 3 received a fluoroscopy-guided glenohumeral joint intra-articular saline injection and supervised physical therapy. Group 4, the placebo group, had only a saline injection. All groups performed a physical therapist-instructed home exercise program (HEP), so those in group 4 can be considered the HEP group. Patients were assessed at 6 weeks, 3 months, 6 months, and 1 year using ROM, the SPADI, and the SF-36 as outcome measures. Supervised physical therapy consisted of 12 one-hour sessions over a 4-week period. The interventions were based on whether the patient was in a more acute "capsulitis" stage or in a more chronic stage. Those in the acute group received pain-relieving modalities (transcutaneous electrical nerve stimulation and ice), low-grade joint mobilizations, and active ROM exercises. Those in the chronic group were treated with therapeutic ultrasound, high-grade joint mobilizations, active and active assisted ROM exercises, as well as isometric exercises. At 6 weeks, the corticosteroid injection/physical therapy group demonstrated the largest change in the SPADI score; however, the scores were not statistically different from the corticosteroid injection-only group. Moreover, both corticosteroid injection groups improved significantly more than the 2 noncorticosteroid injection groups. At 6 months, the SPADI scores were similar among all 4 groups; however, active and passive ROM were better in the corticosteroid injection/physical therapy group. There were no differences in outcomes among the 4 groups at 12 months. This study concluded that at 6 weeks, intra-articular injection alone or with supervised therapy is more effective than 12 sessions of supervised physical therapy or a HEP. Although this study was well controlled, the placebo group (intra-articular saline injection and a HEP) is considered by others to be an effective treatment for adhesive capsulitis.^{19,61}

I Ryans et al¹⁷ also investigated the effect of steroid injections and physiotherapy, performing both glenohumeral joint intra-articular and subacromial injections. Patients were classified as having adhesive capsulitis and included in this study if they had a painful shoulder in the fifth cervical nerve root dermatome distribution of more than 4 weeks and less than 6 months in duration, and a limitation of active and passive range of movement greater than 25% in abduction and external rotation compared to the uninjured, contralateral shoulder. Patients (n = 80) were assessed in a randomized, blinded, placebo-controlled study, and randomly assigned to 4 groups as per the study by Carette et al,²³ except that in this study they did

not use fluoroscopy-guided injections, and only 8 sessions of physiotherapy over a 4-week period were delivered. The physiotherapy program included proprioceptive neuromuscular facilitation, mobilization, interferential electrical stimulation, and exercise. The Shoulder Disability Questionnaire (SDQ), a 16-item functional disability questionnaire; active and passive ROM; global self-rated disability using a visual analog scale (VAS); and pain using a VAS were used to assess outcomes. All groups performed a standardized HEP of stretching, so the placebo group can be considered the HEP group. At 6 weeks, the 2 injection groups significantly improved in the SDQ compared to the other 2 groups; however, patients treated in supervised physiotherapy gained significantly more external rotation motion. All groups significantly improved by 16 weeks, and no difference was noted among groups. A limitation of this study is that only 71% of the patients completed the study at 16 weeks. The most common reason of attrition was failure to improve, occurring most often in the placebo/HEP group. The authors recommended the use of intra-articular and subacromial corticosteroid injections to provide short-term improvements (6 weeks) for relieving shoulder disability and physiotherapy for improving external rotation ROM.

II Bulgen et al¹⁹ compared 4 intervention groups: paired intra-articular and subacromial injections, joint mobilization, ice/proprioceptive neuromuscular facilitation, and no treatment (pendulum exercise performed at home) in a prospective randomized study of 41 patients. Criteria for inclusion were pain in the shoulder for at least 1 month, sleep disturbance at night due to pain, inability to lie on the affected shoulder, restriction in all active and passive shoulder movements, and a reduction in external rotation ROM of at least 50%. Pain, using a VAS, and shoulder ROM were used for outcome measures. Pain was significantly reduced and ROM was significantly improved by the fourth week of treatment for all groups, and improvement continued until 6 months. Improvement was greatest in the injection group, reaching statistical significance for improved motion, but not pain, at 4 weeks. No significant differences in outcomes were seen among the groups at 6 months. The study concluded that there is little long-term advantage of one treatment over the other; however, steroid injections improve ROM and, to a lesser extent, pain in the first 4 weeks.

II van der Windt et al¹²⁹ compared intra-articular injections (average of 2.2 per patient) to physical therapy in a prospective randomized controlled trial on 109 patients with a stiff, painful shoulder (capsular syndrome). The inclusion criterion for this study was painful, restricted glenohumeral passive mobility. In this study population, external rotation was more limited than abduction and internal rotation. Physical therapy consisted of twelve

30-minute sessions involving passive joint mobilization and exercises. Heat, ice, and electrical stimulation could also be used to reduce pain, at the therapist's discretion. Treatment was varied based on symptom severity. Outcome assessment included the SDQ, a VAS for pain, and ROM. At 7 weeks, 77% of the patients treated with injections were considered treatment "successes," compared to only 46% of those treated with physical therapy. Treatment success was based on the patient's self-rating of having made complete recovery or much improvement. Statistically significant differences between groups were found in nearly all outcome measures. At 26 and 52 weeks, there were no differences noted between the 2 groups for any of the outcome measures.

II Arslan and Çeliker⁴ randomly allocated 20 patients with adhesive capsulitis to receive either an intra-articular glenohumeral joint steroid injection or a combination of physical therapy and a nonsteroidal anti-inflammatory drug. Patients were classified with adhesive capsulitis and included in the study if they had less than 50% of normal motion. Physical therapy consisted of hot packs, ultrasound (3.5 W/cm² for 5 minutes), passive glenohumeral stretching exercises, and wall climb. The mean duration of physical therapy was 2 weeks, and both groups performed a HEP. ROM and pain outcome measures revealed similar improvements in both groups at 2 weeks and 12 weeks. The authors concluded that steroid injections alone were as effective as physical therapy for improving ROM and reducing pain.

II de Jong et al³⁸ performed a prospective, randomized, double-blind study in which they investigated the use of low-dose (10 mg) and high-dose (40 mg) triamcinolone acetonide (corticosteroid) intra-articular injections given to patients with adhesive capsulitis. Patients were classified with adhesive capsulitis and included in the study if they had a spontaneous onset of shoulder pain or the shoulder pain was caused by a minor trauma; restriction of passive ROM of the glenohumeral joint, described as a 45° or more reduction of external rotation; and disruption of sleep while lying on the affected shoulder. Thirty-two patients were given the low-dose injection, whereas 25 received the high-dose injection. Three injections were given at weekly intervals, with no concurrent intervention used. Outcomes included a pain VAS, passive ROM, disturbances of sleep, and functional shoulder and arm ability measured using a 4-point ordinal scale. Measurements were taken at 1, 3, and 6 weeks. Significant differences in pain were found at all follow-up intervals, favoring the high-dose group. Both sleep disturbance and functional ability were significantly better in the higher-dose group. While this study did not provide information that steroid injections were more efficacious than other interventions, it demonstrated that higher-dose

corticosteroids (40 mg compared to 10 mg) had greater effect on relieving symptoms related to adhesive capsulitis.

I Jacobs et al⁵⁶ randomized 53 patients with frozen shoulder to a group that received manipulation under anesthesia or a group that received an intra-articular steroid injection with distention. The criteria for patients to be included in this study were not clearly defined. Exclusion criteria included additional or alternative pathologies (diabetes types 1 and 2) and patients who had received a steroid injection into the affected shoulder before referral. The manipulation consisted of forced motion using a short lever into all end ranges. At short-term intervals as well as at the 2-year follow-up, the authors found no difference between the 2 groups in the Constant score, a pain VAS, and the SF-36. The authors, therefore, recommended intra-articular steroid injection with distention over manipulation under anesthesia, because the clinical outcome was the same but with less risk.

II Bal and colleagues⁶ examined the difference between intra-articular corticosteroid injections and intra-articular serum physiologic injections, both followed by a 12-week HEP, for patients with adhesive capsulitis. Inclusion criteria were the presence of shoulder pain with at least 25% limitation of both active and passive movements of the glenohumeral joint in at least 2 directions, between 6 weeks and 6 months of symptom duration, and no treatment other than analgesics in the previous 6 months. At the second week, changes in abduction ROM, SPADI total score, and SPADI pain score and medians of University of California, Los Angeles end-result scores were statistically better in the corticosteroid group. However, none of the differences between groups remained significant at 12 weeks.

I Seventy-one patients with primary frozen shoulder were randomly assigned to receive glenohumeral joint versus subacromial corticosteroid injections.⁹³ All injections were performed under diagnostic ultrasound-guided conditions. Both groups were treated with nonsteroidal anti-inflammatory medication and a HEP consisting of gentle active assisted and passive flexion, abduction, external rotation, adduction, and sleeper stretch exercises. The instructions for the HEP consisted of performing each exercise for 10 repetitions with a 5- to 10-second hold time to tolerance, 3 to 5 times daily. Strengthening exercises were not performed until shoulder pain subsided. Patients were diagnosed with primary frozen shoulder and included in this study if they had limitations of both active and passive motion in at least 2 directions (abduction and forward flexion less than 100°, external rotation less than 20°, or internal rotation less than reaching behind the back to the spinous process of the third lumbar vertebra). Patients demonstrating

secondary frozen shoulder due to rotator cuff tendinopathy, calcific tendinitis, or osteoarthritis based on diagnostic ultrasound and radiography were excluded from the study. Data were collected at preinjection and at 3, 6, and 12 weeks after the injection. A pain VAS, the Constant score, and ROM were used as outcome measures. The authors determined that both groups had marked improvement in all parameters, with only the pain VAS at 3 weeks demonstrating a statistically significant difference favoring the intra-articular injection group. No differences between groups were noted at 6 and 12 weeks. The Constant score and ROM measures were not statistically different at any time frame postinjection. The authors concluded that a subacromial corticosteroid injection was as effective as an intra-articular corticosteroid injection. They could not rule out all forms of rotator cuff tendinopathy using ultrasonography. Therefore, many patients thought to have primary frozen shoulder may have had secondary frozen shoulder stemming from rotator cuff tendinopathy. The authors also recognized that they did not use any control group that only performed exercise. The study highlighted the idea that because subacromial tissue may be involved in primary frozen shoulder, subacromial injections may be added as a potential intervention strategy. This study also highlighted the diagnostic difficulty of distinguishing primary from secondary frozen shoulder.

IV Lorbach et al⁷⁰ reported on the effectiveness of fluoroscopic-guided intra-articular corticosteroid injections. Twenty-five patients (9 male, 16 female) with a mean age of 49 years and stage 2 adhesive capsulitis were included in this study. Patients were included if their clinical findings were consistent with stage 2 Reeves classification criteria.⁷⁰ Patients with diabetes mellitus, previous intra-articular injections, or signs of glenohumeral joint osteoarthritis were excluded from the study. Treatment consisted of 3 fluoroscopically guided intra-articular cortisone injections, with a 4-week interval between injections. Physical therapy was started after 4 weeks and consisted of joint mobilization twice a week and instruction in a daily stretching exercise program in pain-free ranges of movement. Outcome measures were ROM, ASES score, and the SF-36 administered at pretreatment and at 4, 8, 12, 24, and 52 weeks. The results demonstrated significant improvement in all outcome measures at 4 weeks and further progress being made through 1 year. The most significant gains were noted in the first 4 weeks following the first injection. Interestingly, ROM measures compared to the uninvolved side at 1 year still demonstrated significant relative restrictions of 24° for flexion, 25° for abduction, and 15° for external rotation. Internal rotation ROM was not found to be different from side to side at 1 year. The ASES score, although dramatically improved at 1 year, still only averaged 73 of 100 possible points. This study demonstrated the short-term benefit of intra-articular ste-

roid injections in patients with primary adhesive capsulitis. Although 90% of the patients were satisfied at 1-year follow-up, approximately 25% still had significant ROM restrictions when compared to the uninvolved extremity.

I Blanchard et al¹³ performed a systematic literature review assessing the effectiveness of corticosteroid injections compared to physiotherapy interventions for adhesive capsulitis. Six studies were determined eligible for inclusion. The authors reported that at 6 to 7 weeks there was a medium effect in favor of corticosteroid injections when compared to physiotherapy interventions. Small effects were also present in the time range from 12 to 52 weeks. Their conclusion was that corticosteroid injections were more beneficial than physiotherapy interventions in the treatment of adhesive capsulitis at short term and to a lesser extent at long term. The review also showed that physiotherapy interventions led to a better outcome than when patients did not receive any intervention (control group) and therefore offer a positive alternative for patients who declined injection.

A Intra-articular corticosteroid injections combined with shoulder mobility and stretching exercises are more effective in providing short-term (4-6 weeks) pain relief and improved function compared to shoulder mobility and stretching exercises alone.

PATIENT EDUCATION

Patient education is central to each patient-physical therapist interaction and critical to the rehabilitative management of patients with adhesive capsulitis. The insidious nature of adhesive capsulitis is perplexing to patients, who often have concerns about serious medical conditions. Patients generally experience exquisite pain in the early stages of adhesive capsulitis, yet their recovery follows a fairly predictable course. Describing the pathology (synovitis/angiogenesis progressing to fibrosis) can allay fears and prepare them for the staged progression of the condition and recovery. Encouraging activity modification, while emphasizing functional pain-free ROM, is important to prevent self-imposed immobilization. Patients need to understand that exercises should be performed without significant pain.

I Diercks and Stevens³⁹ investigated the use of “supervised neglect” compared to aggressive therapy in 77 patients with adhesive capsulitis. Patients were classified as having adhesive capsulitis and included in this study if they had more than 50% motion restriction of the glenohumeral joint in all directions for a period of 3 months or more. The group of patients defined as receiving “supervised neglect” was provided with “an explanation

of the natural course of the disease,” instruction in pendulum exercises, and active stretching techniques within the pain-free ROM. The aggressive therapy group was treated in supervised therapy with exercise and manual techniques up to and beyond their pain threshold. These patients were also encouraged to perform a HEP of maximal reaching. At 24-month follow-up, 89% of the patients in the “supervised neglect” group achieved a Constant score of 80 or greater out of 100, versus 64% of those in the aggressively mobilized group, indicating that the “supervised neglect” treatment approach was superior to more aggressive therapy.

B Clinicians should utilize patient education that (1) describes the natural course of the disease, (2) promotes activity modification to encourage functional, pain-free ROM, and (3) matches the intensity of stretching to the patient’s current level of irritability.

MODALITIES

Heating or electrical modalities theoretically can have positive benefit on pain in the treatment of patients with adhesive capsulitis. However, the impact of a singular modality on the natural course of adhesive capsulitis is difficult to determine, as therapeutic modalities are typically applied as adjunctive treatments to manual therapy and/or therapeutic exercises.

II Dogru et al⁴⁰ conducted a randomized controlled trial analyzing the effects of therapeutic ultrasound for the treatment of adhesive capsulitis in 49 patients. The criteria to be included in this study were shoulder pain for a minimum of 3 months with no major trauma, greater than 25% loss of shoulder motion in all planes of movement, pain with motion with a minimum VAS score of 40 mm, and normal findings on radiographs of the glenohumeral joint. Ten ultrasound treatments (3-MHz frequency for 10 minutes at 1.5 W/cm²) were performed to the affected shoulder over a 2-week period. The control group was treated with sham ultrasound using an inactive unit. Both groups of patients also received superficial thermotherapy provided via an electrical hot pack at 60°C for 20 minutes, followed by pendulum and active ROM exercises. SF-36 scores, SPADI scores, pain with motion, and ROM measurements for flexion, external rotation, and internal rotation were taken at the end of the 10th treatment session and again 3 months after entering the study. ROM improvements were greater in the ultrasound versus the sham group, reaching statistical significance for internal and external rotation immediately posttreatment and at the 3-month follow-up, and for flexion and abduction immediately posttreatment. However, these improvements of ROM were not correlated with pain, disability, or general health status.

IV Mao et al⁷⁴ utilized arthrography to quantify changes in glenohumeral joint volume in 12 patients with adhesive capsulitis treated with deep heating modalities as adjunctive treatments to passive mobilization and a home program. Half of the 12 participants received ultrasound (1 MHz, continuous, 0.8-1.2 W/cm² for 8 minutes), whereas the other patients received continuous shortwave diathermy for 20 minutes. Study inclusion criteria were a history of pain and stiffness in the shoulder for more than 1 month, shoulder pain elicited at end range of all planes of motion, and shoulder ROM limited to less than 140° of flexion, 120° of abduction, 70° of internal rotation, and 50° of external rotation. Treatments were performed 2 to 3 times per week for 4 to 6 weeks. The authors found that an increase in capsular volume was associated with an increase in external rotation ROM. The actual efficacy of the heating modalities could not be determined because no control group was used. Significant differences in outcome between the 2 forms of deep heating are also unknown, as no analysis was performed.

II Guler-Uysal and Kozanoglu⁴⁶ conducted a prospective, randomized trial of 42 patients with adhesive capsulitis, comparing the use of moist hot pack and continuous shortwave diathermy to Cyriax-inspired manual techniques such as joint mobilizations and transverse friction massage. Patients were classified as having adhesive capsulitis and included in this study if they had shoulder pain for a minimum of 2 months with no major precipitating shoulder trauma, loss of active and passive shoulder ROM, pain with shoulder motion, and a minimum VAS pain score of 30 mm. Manual treatments were performed for 1 hour 3 times per week. Patients in the modalities group received moist hot pack for 20 minutes followed by 20 minutes of shortwave diathermy (220 V/50 Hz at 27.12-MHz oscillation frequency). Both groups performed active stretching and pendulum exercises following their sessions and a HEP. Treatment was continued until patients had achieved at least 80% of the normal passive ROM of the shoulder, which the authors defined as 180° of flexion and abduction, 70° of internal rotation, and 90° of external rotation. Ninety-five percent of patients who received manual techniques achieved the 80% milestone by the end of the second week of treatment, compared to only 65% of those who received the heating modalities. The authors concluded that manual therapy treatments were more efficacious than passive heating, but because no control group was included, it is difficult to conclude whether superficial and deep heating was any more effective than simple home stretching in the treatment of patients with adhesive capsulitis. Because the majority of patients had a rapid response, it also appears that the adhesive capsulitis diagnosis was loosely applied to patients presenting with shoulder pain and that true adhesive capsulitis was likely not present in many of the patients included in the study.

II Leung and Cheing⁶⁷ recently sought to answer whether superficial and deep heating modalities were useful adjunctive treatments to a self-stretching program. The authors randomly assigned 30 patients in the stiffness stage of adhesive capsulitis, defined as having idiopathic pain and loss of motion in the shoulder of at least 8 weeks' duration, to 3 groups: hot pack and self-stretching, shortwave diathermy and stretching, and stretching alone. Patients were treated for 20 minutes 3 times per week for 4 weeks. The hot-pack treatment utilized an electrical hot pack at 63°C. Shortwave diathermy was provided at a comfortable heating intensity via a 27.12-MHz wave through anterior and posterior electrodes. At the 4-week follow-up, all groups had improvements in the ASES score and ROM measurements. Patients treated with shortwave diathermy demonstrated significantly greater improvement in ROM compared to the other treatment groups, and there were no significant differences between groups treated with superficial heating and stretching versus stretching alone. In addition, most improvements were noted in the first 2 weeks of treatment.

II Cheing and colleagues²⁶ designed a study in which 70 patients with frozen shoulder were randomly assigned to receive electroacupuncture plus exercise, interferential electrotherapy plus exercise, or no treatment for 4 weeks. Patients were included in this study if they had pain in 1 shoulder, night pain, and restricted active and passive shoulder ROM. The exercise groups received 10 treatment sessions. After the intervention, both treatment groups improved significantly on the Constant-Murley assessment score and the pain VAS, whereas the control group did not change. These differences were maintained at the 6-month follow-up, with no significant differences noted between the 2 intervention groups.

III In a nonrandomized prospective study of 50 patients with adhesive capsulitis, Rizk et al¹⁰⁹ investigated the application of transcutaneous electrical nerve stimulation (50-150 Hz for 10 minutes) together with prolonged end-range stretching performed with overhead pulleys. Patients were classified as having adhesive capsulitis and included in this study if they had pain on resisted motions, exclusive restriction of glenohumeral joint motion with maximum passive ROM not exceeding 110° of abduction (with external rotation), 50° of external rotation, 70° of internal rotation, and 140° of flexion. The comparison group received "standard physical therapy," including superficial heating modalities, and a combination of active and passive mobilization. Significant improvement in overall ROM was found in the group treated with transcutaneous electrical nerve stimulation; however, this may have been due to the prolonged end-range stretching that was concurrently provided.

C Clinicians may utilize shortwave diathermy, ultrasound, or electrical stimulation combined with mobility and stretching exercises to reduce pain and improve shoulder ROM in patients with adhesive capsulitis.

JOINT MOBILIZATION

Several studies have examined the effect of joint mobilization in patients with adhesive capsulitis, and although there is evidence that it may be beneficial, there is little evidence to support superior efficacy over other interventions.^{19,57,91,130,131} Future research designs where patients are classified into (1) treatment groups with physical impairments that presumably best respond to joint mobilization¹³¹ and (2) where the mobilization force is best matched to the tissue irritability of the patient⁶⁰ may provide a clear indication of whether joint mobilization is beneficial for patients with adhesive capsulitis.

II Vermeulen et al¹³¹ performed a randomized prospective study (n = 100) comparing high-grade (grades III and IV) to low-grade (grades I and II) mobilization techniques without the inclusion of exercises. Patients were included in this study if they had unilateral adhesive capsulitis, defined as greater than 50% loss of passive movement of the shoulder joint in 1 or more directions and duration of complaints for more than 3 months. There was no control group, and no modalities or HEP were performed. The patients were treated 2 times a week for 30 minutes for 12 weeks and assessed at 3, 6, and 12 months using the Shoulder Rating Questionnaire, SDQ, SF-36, ROM, and a pain VAS. Inferior, anterior, and posterior glide techniques were used in addition to distraction techniques. The authors found significant improvement in both groups occurring in the first 3 months. The high-grade mobilization group did better, but only a minority of comparisons reached statistical significance, and the overall difference between the 2 interventions was small. After 3 months, approximately 25% of the patients received other therapies (medication, injection), but there was no significant difference in long-term outcomes between these patients and those who were only treated with joint mobilization for the 3-month treatment period. This study demonstrates that grade I and II mobilization (not tensioning the tissue to end range) can be effective in not only improving pain but also increasing ROM and function.

II Bulgen et al¹⁹ compared 4 intervention groups: paired intra-articular and subacromial injections, joint mobilization, ice/proprioceptive neuromuscular facilitation, and no treatment (pendulum exercises) in a prospective randomized study of 41 patients. The criteria for patients to be included were pain in the shoulder for at least 1 month, night pain while sleeping, inability to

lie on the affected shoulder, restriction in all active and passive shoulder motions, and a reduction in external rotation motion of at least 50%. Patients treated with joint mobilization and a HEP significantly improved in the first 4 weeks, but slightly less than patients receiving intra-articular and subacromial injections. The group treated with joint mobilization did no better than the other 2 groups (proprioceptive neuromuscular facilitation/ice/HEP and just pendulum exercises performed at home). At 6 months, the mobilization group significantly improved relative to initial ROM and pain measures, but no difference was noted when compared to the other treatment groups.

II Nicholson⁹¹ compared a group of patients with adhesive capsulitis who received joint mobilization and active exercise (n = 10) to a group receiving just exercise (n = 10). The criteria for patients to be included in this study were shoulder pain and limited passive motion of the glenohumeral joint. Following 4 weeks of treatment, they found significantly improved ROM and reduced pain in both groups, with the only difference between groups being a slightly greater improvement (7°) in passive abduction for the mobilization group. Limitations of this study were limited measures of pain and ROM and only a 4-week follow-up.

II Chen and colleagues²⁷ compared a group of patients with shoulder pain and stiffness who received joint mobilization, exercise, and advice (n = 39) to a group receiving just exercise and advice (n = 39). The criteria for patients to be included in this study were unilateral shoulder pain reproduced during shoulder motion, less than 140° of active shoulder flexion and abduction ROM, a greater than 10-cm hand-behind-back deficit compared to the unaffected side, and pain and/or stiffness during accessory movement testing of the joints in the shoulder region. Participants received a maximum of ten 30-minute therapy sessions over an 8-week period. At 1 and 6 months, there were no statistically significant differences in pain and disability, self-perceived global improvement, or active ROM between the 2 groups.

IV Vermeulen et al¹³⁰ presented a case series of 7 patients with a diagnosis of adhesive capsulitis treated solely with intense end-range mobilization techniques (no exercise or modalities) over a 3-month duration. The diagnostic criteria for adhesive capsulitis were a painful stiff shoulder for at least 3 months, a restriction of more than 50% in passive shoulder abduction, flexion in the sagittal plane, lateral rotation compared to the opposite side, and maximal glenohumeral joint capacity of 15 cc. Patients were excluded from the study if they had diabetes mellitus, sustained a severe trauma, or had osteoarthritis. Patients were treated 2 to 3 times a week, and both ROM and joint volume (measured by arthrography) were used to determine out-

comes. They reported significant improvement in active and passive ROM, pain, and joint volume following treatment.

IV Yang and colleagues¹³⁸ performed a multiple-treatment trial using various combinations of end-range mobilization, midrange mobilization, and mobilization with movement in 28 patients with adhesive capsulitis. Patients were classified as having adhesive capsulitis and included in this study if they had a painful shoulder for at least 3 months with ROM losses of at least 25% in at least 2 directions. Each treatment was given for a 3-week period in different sequences for a total of 12 weeks. They found improved active mobility and self-reported levels of function at 12 weeks. They concluded that end-range mobilization and midrange mobilization were more effective than mobilization with movement in increasing motion and function.

II Tanaka et al¹²⁴ attempted to identify the preferred management for limited glenohumeral motion focusing on frequency of sessions for joint mobilization and self-exercise compliance. One hundred ten patients (52 male, 58 female) with an average age of 63.7 years were enrolled in the study. Study inclusion criteria were painful and limited shoulder motion with an unremarkable medical history and no clinical or radiological findings identifying shoulder pathology. Each patient was treated with a standardized intervention including shoulder joint mobilization and instruction in a HEP. Mobilization techniques were high-intensity mobilizations performed at end range.¹³⁰ The HEP consisted of pendulum and passive stretching exercises, including but not limited to exercises such as wall climbs. Patients were randomly assigned to 1 of 3 frequency-of-treatment groups. The high-frequency group was treated 2 times a week, the moderate-frequency group was treated once a week, and the low-frequency group was treated less than once a week. Measured outcomes were active abduction ROM and the time required (months) to reach ROM plateaus. They also assessed the effect of age, gender, handedness, duration of symptoms before rehabilitation intervention, frequency of sessions for joint mobilization, and self-exercise compliance in a home setting. The results showed no difference in improved motion based on gender; however, better improvement in motion was seen in the involved dominant extremity versus the involved nondominant extremity. The frequency of use of joint mobilization showed no relationship with improved motion or time to motion plateau. However, the improved motion was significantly better and time to plateau shorter in the group that performed a HEP every day. A relationship was seen between longer symptom duration and smaller gains in ROM. This study indicated that greater compliance with the HEP had greater influence on motion return and time to motion plateau than frequency of joint mobilization. A limitation of this study is that the motion cri-

teria limitations for inclusion in this study were not defined. Another limitation is the exclusive use of active abduction as the outcome measure, as opposed to assessing changes in other shoulder motions and/or an accepted outcome tool. Patients may have gained motion in other planes in the different treatment groups that went undetected.

II Johnson et al⁵⁷ investigated the effectiveness of anterior versus posterior glide mobilization on external rotation ROM in 20 patients (4 male and 16 female) with adhesive capsulitis. Patients were classified as having adhesive capsulitis and included in this study if they had external rotation motion restriction and if restriction in external rotation increased as the shoulder was moved toward greater abduction. The pain VAS, a 5-item self-assessment function questionnaire, and external rotation ROM in the highest degree of abduction were used for outcome measures. Patients were initially treated with ultrasound to the anterior capsule or posterior capsule based on treatment with anterior or posterior mobilization, respectively. Mobilization was applied to end range with a sustained stretch of 1 minute. No oscillatory motions were performed. Two techniques for both anterior and posterior glides were chosen, for a total of 15 minutes of sustained stretch at each treatment session. Patients were treated for a total of 6 sessions over 2 to 3 weeks. No HEP was performed. Patients treated with posterior glide mobilization demonstrated significantly greater improvement in external rotation ROM compared to those treated with anterior glide mobilization. This study compared the effect of 2 directions of mobilization on external rotation motion, but did not compare mobilization to other forms of treatment or assess the effect on other motions.

C Clinicians may utilize joint mobilization procedures primarily directed to the glenohumeral joint to reduce pain and increase motion and function in patients with adhesive capsulitis.

TRANSLATIONAL MANIPULATION

IV Roubal et al¹¹⁴ described an alternative treatment method to standard shoulder manipulation for patients with unresponsive adhesive capsulitis. A single session of translational manipulations was performed on 8 patients with recalcitrant adhesive capsulitis following an interscalene brachial plexus block administered by an anesthesiologist. Patients were excluded if they had a history of cancer, significant osteoporosis, MRI or clinically demonstrated rotator cuff tear, or inappropriate cardiovascular history to undergo an interscalene brachial plexus block. A 2-person manipulative technique was used so that 1 clinician could stabilize the scapula while the other performed the translational manipulation. For treatment, an inferior glide

manipulation was followed by a posterior glide manipulation. Initially, all manipulations were preceded by Kaltenborn grade III mobilizations, and if no increased motion was noted after 3 trials, then a Maitland grade V manipulation was performed. Six of 8 patients experienced a significant immediate increase in passive ROM in all directions posttreatment. Two patients demonstrated no change in motion. Following the manipulation, all patients were instructed to perform passive forward flexion for 5 minutes every hour while the interscalene brachial plexus block was in effect. They were subsequently treated in physical therapy daily for 1 week and 3 times a week for 1 to 5 weeks. Therapy consisted of ice, high-volt galvanic electrical stimulation, ultrasound, joint mobilization, and stretching and strengthening exercises. A HEP was used in the first week, consisting of ROM stretching for 5 repetitions of 20 seconds' duration in all directions every 1 to 2 hours. The HEP continued to emphasize stretching in the second week and included strengthening with elastic bands in all directions. On the day of the manipulation, a Medrol (methylprednisolone 4 mg) 1-week dose pack (Pfizer Inc, New York, NY) was initiated for 4 of the patients. The 6 patients who responded to the manipulation had sustained increased function and active and passive motion. No shoulder-specific outcome tool was used in this study. This study provides an alternative option to commonly performed manipulation, but the therapist must carefully screen appropriate patients, have a close relationship with an anesthesiologist, and recognize that not all patients will respond to translational manipulation performed in this manner.

IV Placzek et al¹⁰¹ reported on using the identical manipulative procedure as described by Roubal et al¹¹⁴ in 31 patients (32 shoulders). The average duration of symptoms was 7.8 months and the average number of previous physical therapy treatment sessions was 7.7. Inclusion criteria were decreased function, painful active and passive motion, pain-free resisted testing, and passive mobility deficits with total ROM loss greater than 40% (flexion, abduction, external rotation, internal rotation) while measured under anesthesia. Inclusion criteria also included greater than 2 months' duration of symptoms and no medical contraindications to undergo an interscalene brachial plexus block. Exclusion criteria included a history of cancer, significant osteoporosis, MRI or clinically demonstrated rotator cuff tear, rheumatic disease, prolonged steroid use, recent fracture, upper extremity neurologic deficits, or inappropriate cardiovascular history to undergo an interscalene brachial plexus block. All patients were successfully manipulated. All patients, except the 4 with diabetes mellitus, started the use of oral steroid medication the day before manipulation. Each began a postmanipulation ROM and physical therapy program identical to that described in the study by Roubal et al.¹¹⁴ ROM was assessed premanipulation, immediately post-

manipulation, at discharge from physical therapy (5.3 ± 3.2 weeks), and at a long-term follow-up visit (14.4 months ± 7.3 months). A VAS for pain and a functional outcome measure (Wolfgang Scale) were assessed at initial evaluation, at discharge, and at the long-term follow-up. Significant increased motion was reported immediately postmanipulation, which was maintained or improved at both physical therapy discharge and long-term follow-up. Both pain and function significantly improved at discharge and at long-term follow-up. The authors felt that the inferior translation techniques stretched or disrupted the adhesions within the inferior fold, leading to regaining elevation motion. The posterior translation was felt to restore both external and internal rotation motion by stretching the posterior capsule and rotator cuff interval. The authors concluded that translational gliding could be performed in an outpatient setting and without the potential complications experienced with standard rotatory manipulative techniques typically performed under anesthesia.

C Clinicians may utilize translational manipulation under anesthesia directed to the glenohumeral joint in patients with adhesive capsulitis who are not responding to conservative interventions.

STRETCHING EXERCISES

Stretching exercises appear to influence pain and improve ROM, but not necessarily more than other interventions. Results are inconsistent across multiple studies, demonstrating that stretching results in minimal or no difference in outcomes (at 3-6 months) in patients treated with a therapist-directed HEP or other interventions.^{19,23,61,117} There is only 1 study⁴⁵ for which the authors fully described the exercises performed, with the other studies simply describing the program as active and/or passive exercises. No evidence exists to guide the optimal frequency, number of repetitions, or duration of stretching exercises. Stretching beyond painful limits may result in poorer outcomes. Therefore, stretching intensity that matches the given level of tissue irritability is indicated. As with joint mobilization, future research designs where (1) patients are classified into treatment groups with physical impairments that presumably best respond to stretching exercises¹³¹ and (2) the forces applied are best matched to the tissue irritability of the patient⁶⁰ may provide a clearer indication of whether stretching exercises are beneficial for patients with adhesive capsulitis.

II Kivimäki et al⁶¹ performed a randomized controlled clinical trial (n = 125) comparing a HEP to a combination of manipulation under anesthesia and a HEP. The criteria for patients to be included in this study were gradually increasing shoulder pain and shoulder mobility of no more than 140° of elevation and 30° of external

rotation. Patients were excluded if they had osteoarthritis, traumatic bone or tendon changes in the affected shoulder, or a rotator cuff tear. The HEP, which included pendulum exercises and stretching techniques for the shoulder, was instructed by a physical therapist over 2 therapy sessions and supplemented by a written daily program. The SDQ and shoulder ROM were assessed at 6 weeks and at 3, 6, and 12 months. At 6 weeks and at 3 months, the manipulation group demonstrated statistically greater increase in shoulder flexion ROM (mean, 8°; 95% CI: 0°, 16°). There was no difference in outcomes between groups at any follow-up interval for pain or working ability. Shoulder symptoms had diminished and functional motion had returned by 6 months after randomization. Complete information was obtained for more than 81% of the participants at 3 months and 63% at 12 months. The study demonstrated the equivalence of a therapist-instructed HEP for the treatment of adhesive capsulitis compared to manipulation under anesthesia combined with a HEP; however, there was no control group for comparison.

II Diercks and Stevens³⁹ prospectively followed 77 patients with idiopathic adhesive capsulitis to compare the effects of “intensive” physical therapy to “supervised neglect.” The criterion for patients to be included in this study was more than a 50% motion restriction of the glenohumeral joint in all directions for a period of 3 months or more. The Constant score was assessed every 3 months for 24 months. The intensive physical therapy group performed active exercises up to and beyond the pain threshold, passive stretching, glenohumeral joint mobilization, and a HEP. The “supervised neglect” group was instructed not to exercise past their pain threshold, to do pendulum exercises and active exercises within the painless range of movement, and to resume all activities as tolerated. Both groups had significant ROM and pain improvements; however, 89% of the patients in the “supervised neglect” group achieved a Constant score of greater than 80, compared to only 63% of those in the intense physical therapy group, at 2 years. Interestingly, 64% of the patients in the “supervised neglect” HEP group had achieved a Constant score of at least 80 at the 1-year follow-up, in contrast to none of those in the intense physical therapy group. A conclusion of this study was that aggressive therapy can be detrimental to some patients, especially during the inflammatory stage. The frequency and length of care were not standardized.

II Griggs et al⁴⁵ performed a prospective functional outcome study that included 75 patients classified with stage 2 idiopathic adhesive capsulitis. Outcome measures were pain, ROM, and function using the DASH, the SST, and the SF-36. The mean duration of follow-up was 22 months (12–41 months), and 4 patients were not available for follow-up. All patients performed a HEP of passive stretching

exercises in forward elevation, external rotation, horizontal adduction, and internal rotation. All patients were referred to physical therapy for exercise performance, and the therapist determined the number of visits. Ninety percent (64/71) of the patients reported satisfactory outcomes, 10% (7/71) were not satisfied, and 5 of these 7 underwent manipulation and/or arthroscopic release. Interestingly, although the patients were satisfied, they continued to demonstrate restricted motion relative to their uninvolved side. Patients with the worst perceptions of pain and function of their shoulder prior to treatment tended to have the worst outcomes.

II Lee et al⁶⁵ investigated the effect of exercise with and without steroid injection compared to the outcomes of patients who were just taking analgesics (n = 65) over a 6-week course of treatment. The criteria for patients to be included in this study were not specified. They found that both exercise groups (with and without corticosteroid injections) significantly improved in active abduction and external rotation ROM compared to the group taking analgesics alone. They found that most of the improvement occurred in the first 3 weeks. However, neither the exercise program nor the analgesic medication was described.

II The effect of adding specific scapulothoracic strengthening exercises to a physical therapy program was investigated in patients with adhesive capsulitis.²⁴ Twenty-eight patients (7 males and 21 females) with an average age of 52.1 (range, 32–65) years were included. All patients were evaluated by an orthopaedist and had both radiographs and MRI performed. Inclusion criteria were at least 50% restriction of external rotation, abduction, and flexion compared to the other side; normal anterior/posterior and lateral radiographs; secondary frozen shoulder with type II impingement based on clinical examination and MRI; and secondary frozen shoulder with demonstrated small rotator cuff tear on MRI. Patients were randomly assigned to 2 groups, and each group was treated with active and passive ROM exercises, manual stretching, proprioceptive neuromuscular facilitation, transcutaneous nerve stimulation, and ice. All patients performed a HEP. The experimental group also performed isolated scapular and glenohumeral/scapular muscle strengthening. Exercise intensity was progressed based on pain status, and patients were treated for 6 weeks (30 sessions). A modified Constant score, pain VAS, and ROM were assessed at 6 and 12 weeks. Both groups significantly improved in all outcome measures, with the group treated with scapular strengthening showing statistically greater active elevation ROM at 12 weeks. The authors suggested that the group treated with scapular strengthening improved because the scapulohumeral rhythm was “restored”; however, scapulohumeral rhythm was only visually assessed.

IV Levine et al⁶⁸ reported on a nonoperative-care, retrospective case series that included a standard physical therapy program with nonsteroidal anti-inflammatory medication with or without corticosteroid injection. End points were satisfactory resolution of symptoms with nonoperative care or choosing operative care. They found that 89.5% of 98 patients with adhesive capsulitis responded to nonoperative management. Resolution of symptoms occurred in 52.4% of patients with a combination of physical therapy and nonsteroidal anti-inflammatory

medication, and in an additional 37.1% of patients with a combination of nonsteroidal anti-inflammatory medication, physical therapy, and 1 or more injections. The average time to successful treatment was 3.8 months. No specific program of exercise was described.

B Clinicians should instruct patients with adhesive capsulitis in stretching exercises. The intensity of the exercises should be determined by the patient's tissue irritability level.

CLINICAL GUIDELINES

Summary of Recommendations

E PATHOANATOMICAL FEATURES

Clinicians should assess for impairments in the capsuloligamentous complex and musculotendinous structures surrounding the shoulder complex when a patient presents with shoulder pain and mobility deficits (adhesive capsulitis). The loss of passive motion in multiple planes, particularly external rotation with the arm at the side and in varying degrees of shoulder abduction, is a significant finding that can be used to guide treatment planning.

C RISK FACTORS

Clinicians should recognize that (1) patients with diabetes mellitus and thyroid disease are at risk for developing adhesive capsulitis, and (2) adhesive capsulitis is more prevalent in individuals who are 40 to 65 years of age, female, and have had a previous episode of adhesive capsulitis in the contralateral arm.

B CLINICAL COURSE

Clinicians should recognize that adhesive capsulitis occurs as a continuum of pathology characterized by a staged progression of pain and mobility deficits and that, at 12 to 18 months, mild to moderate mobility deficits and pain may persist, though many patients report minimal to no disability.

F DIAGNOSIS/CLASSIFICATION

Clinicians should recognize that patients with adhesive capsulitis present with a gradual and progressive onset of pain and loss of active and passive shoulder motion in both elevation and rotation. Utilizing the evaluation and intervention components described in these guidelines will assist clinicians in medical screening, differential evaluation of common shoulder musculoskeletal disorders, diagnosing tissue irritability levels, and planning intervention strategies for patients with shoulder pain and mobility deficits.

F DIFFERENTIAL DIAGNOSIS

Clinicians should consider diagnostic classifications other than adhesive capsulitis when the patient's reported activity limitations or impairments of body function and structure are not consistent with the diagnosis/classification section of these guidelines, or when the patient's symptoms are not resolving with interventions aimed at normalization of the patient's impairments of body function.

A EXAMINATION – OUTCOME MEASURES

Clinicians should use validated functional outcome measures, such as the DASH, the ASES, or the SPADI. These should be utilized before and after interventions intended to alleviate the impairments of body function and structure, activity limitations, and participation restrictions associated with adhesive capsulitis.

F EXAMINATION – ACTIVITY LIMITATION AND PARTICIPATION RESTRICTION MEASURES

Clinicians should utilize easily reproducible activity limitation and participation restriction measures associated with their patient's shoulder pain to assess the changes in the patient's level of shoulder function over the episode of care.

E EXAMINATION – PHYSICAL IMPAIRMENT MEASURES

Clinicians should measure pain, active shoulder ROM, and passive shoulder ROM to assess the key impairments of body function and body structures in patients with adhesive capsulitis. Glenohumeral joint accessory motion may be assessed to determine translational glide loss.

A INTERVENTIONS – CORTICOSTEROID INJECTIONS

Intra-articular corticosteroid injections combined with shoulder mobility and stretching exercises are more effective in providing short-term (4-6 weeks) pain relief and improved function compared to shoulder mobility and stretching exercises alone.

B INTERVENTIONS – PATIENT EDUCATION

Clinicians should utilize patient education that (1) describes the natural course of the disease, (2) promotes activity modification to encourage functional, pain-free ROM, and (3) matches the intensity of stretching to the patient's current level of irritability.

C INTERVENTIONS – MODALITIES

Clinicians may utilize shortwave diathermy, ultrasound, or electrical stimulation combined with mobility and stretching exercises to reduce pain and improve shoulder ROM in patients with adhesive capsulitis.

C INTERVENTIONS – JOINT MOBILIZATION

Clinicians may utilize joint mobilization procedures primarily directed to the glenohumeral joint to reduce pain and increase motion and function in patients with adhesive capsulitis.

C INTERVENTIONS – TRANSLATIONAL MANIPULATION

Clinicians may utilize translational manipulation under anesthesia directed to the glenohumeral joint in patients with adhesive capsulitis who are not responding to conservative interventions.

B INTERVENTIONS – STRETCHING EXERCISES

Clinicians should instruct patients with adhesive capsulitis in stretching exercises. The intensity of the exercises should be determined by the patient's tissue irritability level.

AFFILIATIONS AND CONTACTS

AUTHORS

Martin J. Kelley, DPT
Musculoskeletal Team Leader
Good Shepherd Penn Partners
Philadelphia, Pennsylvania
martin.kelley@uphs.upenn.edu

Michael A. Shaffer, MSPT
Coordinator of Sports Rehabilitation
University of Iowa Sports Medicine
Clinical Specialist
Department of Rehabilitation
Therapies
University of Iowa Hospitals
and Clinics
Iowa City, Iowa
michael-shaffer@uiowa.edu

John E. Kuhn, MD
Associate Professor of Orthopaedic
Surgery and Rehabilitation
School of Medicine
Vanderbilt University
Nashville, Tennessee
j.kuhn@vanderbilt.edu

Lori A. Michener, PT, PhD
Professor
Department of Physical Therapy
Virginia Commonwealth University-
Medical College of Virginia
Richmond, Virginia
lamichen@vcu.edu

Amee L. Seitz, DPT, PhD
Assistant Professor
Department of Physical Therapy
Bouvé College of Health Sciences

Northeastern University
Boston, Massachusetts
a.seitz@neu.edu

Tim L. Uhl, PT, PhD
Associate Professor
Director, Musculoskeletal Laboratory
Department of Rehabilitation Science
College of Health Sciences
University of Kentucky
Lexington, Kentucky
tluhl2@uky.edu

Joseph J. Godges, DPT, MA
ICF-based Clinical Practice Guidelines
Coordinator
Orthopaedic Section, APTA, Inc
La Crosse, Wisconsin
icf@orthopt.org
Associate Professor
Division of Biokinesiology
and Physical Therapy
University of Southern California
Los Angeles, California
godges@usc.edu

Philip McClure, PT, PhD
Professor
Department of Physical Therapy
Arcadia University
Glenside, Pennsylvania
mcclure@arcadia.edu

REVIEWERS

Roy D. Altman, MD
Professor of Medicine
Division of Rheumatology
and Immunology

David Geffen School of Medicine
at UCLA
Los Angeles, California
journals@royaltman.com

Todd Davenport, DPT
Associate Professor
Department of Physical Therapy
University of the Pacific
Stockton, California
tdavenport@pacific.edu

George J. Davies, DPT, MEd, MA
Professor
Graduate Program in Physical
Therapy
Armstrong Atlantic State
University
Savannah, Georgia
george.davies@armstrong.edu

John DeWitt, DPT
Director of Post-Professional
Programs
Clinical Assistant Professor
The Ohio State University
Columbus, Ohio
john.dewitt@osumc.edu

Helene Fearon, DPT
Fearon & Levine Consulting
Phoenix, Arizona
helenefearon@fearonlevine.com

Amanda Ferland, DPT
Clinic Director
MVP Physical Therapy
Federal Way, Washington
aferland@mvppt.com

Paula M. Ludewig, PT, PhD
Associate Professor
Program in Physical Therapy
Department of Physical Medicine
& Rehabilitation
University of Minnesota
Minneapolis, Minnesota
ludew001@umn.edu

Joy MacDermid, PT, PhD
Associate Professor
School of Rehabilitation Science
McMaster University
Hamilton, Ontario, Canada
macderj@mcmaster.ca

James W. Matheson, DPT
President and Clinic Director
Catalyst Sports Medicine
Hudson, Wisconsin
jw@eipconsulting.com

Paul J. Roubal, DPT, PhD
Physical Therapy Specialists, PC
Troy, Michigan
thebosspr@comcast.net

Leslie Torburn, DPT
Principal and Consultant
Silhouette Consulting, Inc
San Carlos, California
torburn@yahoo.com

Kevin Wilk, DPT
Associate Clinical Director
Champion Sports Medicine
Physiotherapy Associates
Birmingham, Alabama
kwilkpt@hotmail.com

REFERENCES

1. American Physical Therapy Association. Guide to physical therapist practice. Second edition. *Phys Ther*. 2001;81:9-746.
2. Angst F, Goldhahn J, Drerup S, Aeschlimann A, Schwyzer HK, Simmen BR. Responsiveness of six outcome assessment instruments in total shoulder arthroplasty. *Arthritis Rheum*. 2008;59:391-398. <http://dx.doi.org/10.1002/art.23318>
3. Angst F, Goldhahn J, Pap G, et al. Cross-cultural adaptation, reliability and validity of the German Shoulder Pain and Disability Index (SPADI). *Rheumatology (Oxford)*. 2007;46:87-92. <http://dx.doi.org/10.1093/rheumatology/ke1040>
4. Arslan S, Çeliker R. Comparison of the efficacy of local corticosteroid injection and physical therapy for the treatment of adhesive capsulitis. *Rheumatol Int*. 2001;21:20-23. <http://dx.doi.org/10.1007/s002960100127>
5. Aydeniz A, Gursoy S, Guney E. Which musculoskeletal complications are most frequently seen in type 2 diabetes mellitus? *J Int Med Res*. 2008;36:505-511. <http://dx.doi.org/10.1177/147323000803600315>
6. Bal A, Eksioğlu E, Gulec B, Aydog E, Gurcay E, Cakci A. Effectiveness of corticosteroid injection in adhesive capsulitis. *Clin Rehabil*. 2008;22:503-512. <http://dx.doi.org/10.1177/0269215508086179>
7. Balci N, Balci MK, Tüzüner S. Shoulder adhesive capsulitis and shoulder range of motion in type II diabetes mellitus: association with diabetic complications. *J Diabetes Complications*. 1999;13:135-140. [http://dx.doi.org/10.1016/S1056-8727\(99\)00037-9](http://dx.doi.org/10.1016/S1056-8727(99)00037-9)
8. Beaton DE, Katz JN, Fossel AH, Wright JG, Tarasuk V, Bombardier C. Measuring the whole or the parts? Validity, reliability, and responsiveness of the Disabilities of the Arm, Shoulder and Hand outcome measure in different regions of the upper extremity. *J Hand Ther*. 2001;14:128-146.
9. Bencardino JT, Beltran J, Rosenberg ZS, et al. Superior labrum anterior-posterior lesions: diagnosis with MR arthrography of the shoulder. *Radiology*. 2000;214:267-271.
10. Bergbom S, Boersma K, Overmeer T, Linton SJ. Relationship among pain catastrophizing, depressed mood, and outcomes across physical therapy treatments. *Phys Ther*. 2011;91:754-764. <http://dx.doi.org/10.2522/ptj.20100136>
11. Binder AI, Bulgen DY, Hazleman BL, Roberts S. Frozen shoulder: a long-term prospective study. *Ann Rheum Dis*. 1984;43:361-364.
12. Binder AI, Bulgen DY, Hazleman BL, Tudor J, Wraight P. Frozen shoulder: an arthrographic and radionuclear scan assessment. *Ann Rheum Dis*. 1984;43:365-369.
13. Blanchard V, Barr S, Cerisola FL. The effectiveness of corticosteroid injections compared with physiotherapeutic interventions for adhesive capsulitis: a systematic review. *Physiotherapy*. 2010;96:95-107. <http://dx.doi.org/10.1016/j.physio.2009.09.003>
14. Blevins FT, Pollo FE, Torzilli PA, Warren RF. Effect of humeral head component size on hemiarthroplasty translations and rotations. *J Shoulder Elbow Surg*. 1998;7:591-598.
15. Bot SD, Terwee CB, van der Windt DA, Bouter LM, Dekker J, de Vet HC. Clinimetric evaluation of shoulder disability questionnaires: a systematic review of the literature. *Ann Rheum Dis*. 2004;63:335-341.
16. Bowman CA, Jeffcoate WJ, Patrick M, Doherty M. Bilateral adhesive capsulitis, oligoarthritis and proximal myopathy as presentation of hypothyroidism. *Br J Rheumatol*. 1988;27:62-64.
17. Bridgman JF. Periarthritis of the shoulder and diabetes mellitus. *Ann Rheum Dis*. 1972;31:69-71.
18. Bulgen DY, Binder A, Hazleman BL, Park JR. Immunological studies in frozen shoulder. *J Rheumatol*. 1982;9:893-898.
19. Bulgen DY, Binder AI, Hazleman BL, Dutton J, Roberts S. Frozen shoulder: prospective clinical study with an evaluation of three treatment regimens. *Ann Rheum Dis*. 1984;43:353-360.
20. Bunker TD, Anthony PP. The pathology of frozen shoulder. A Dupuytren-like disease. *J Bone Joint Surg Br*. 1995;77:677-683.
21. Bunker TD, Reilly J, Baird KS, Hamblen DL. Expression of growth factors, cytokines and matrix metalloproteinases in frozen shoulder. *J Bone Joint Surg Br*. 2000;82:768-773.
22. Cakir M, Samanci N, Balci N, Balci MK. Musculoskeletal manifestations in patients with thyroid disease. *Clin Endocrinol (Oxf)*. 2003;59:162-167. <http://dx.doi.org/10.1046/j.1365-2265.2003.01786.x>
23. Carette S, Moffet H, Tardif J, et al. Intraarticular corticosteroids, supervised physiotherapy, or a combination of the two in the treatment of adhesive capsulitis of the shoulder: a placebo-controlled trial. *Arthritis Rheum*. 2003;48:829-838. <http://dx.doi.org/10.1002/art.10954>
24. Çelik D. Comparison of the outcomes of two different exercise programs on frozen shoulder. *Acta Orthop Traumatol Turc*. 2010;44:285-292. <http://dx.doi.org/10.3944/AOTT.2010.2367>
25. Chard MD, Hazleman R, Hazleman BL, King RH, Reiss BB. Shoulder disorders in the elderly: a community survey. *Arthritis Rheum*. 1991;34:766-769.
26. Cheing GL, So EM, Chao CY. Effectiveness of electroacupuncture and interferential electrotherapy in the management of frozen shoulder. *J Rehabil Med*. 2008;40:166-170. <http://dx.doi.org/10.2340/16501977-0142>
27. Chen JF, Ginn KA, Herbert RD. Passive mobilisation of shoulder region joints plus advice and exercise does not reduce pain and disability more than advice and exercise alone: a randomised trial. *Aust J Physiother*. 2009;55:17-23.
28. Clark J, Sidles JA, Matsen FA. The relationship of the glenohumeral joint capsule to the rotator cuff. *Clin Orthop Relat Res*. 1990:29-34.
29. Clark JM, Harryman DT, 2nd. Tendons, ligaments, and capsule of the rotator cuff. Gross and microscopic anatomy. *J Bone Joint Surg Am*. 1992;74:713-725.
30. Clarke GR, Willis LA, Fish WW, Nichols PJ. Preliminary studies in measuring range of motion in normal and painful stiff shoulders. *Rheumatol Rehabil*. 1975;14:39-46.
31. Codman EA. *Rupture of the Supraspinatus Tendon and Other Lesions in or About the Subacromial Bursa*. Boston, MA: Thomas Todd; 1934.
32. Conboy VB, Morris RW, Kiss J, Carr AJ. An evaluation of the Constant-Murley shoulder assessment. *J Bone Joint Surg Br*. 1996;78:229-232.
33. Connell D, Padmanabhan R, Buchbinder R. Adhesive capsulitis: role of MR imaging in differential diagnosis. *Eur Radiol*. 2002;12:2100-2106. <http://dx.doi.org/10.1007/s00330-002-1349-7>
34. Constant CR, Murley AH. A clinical method of functional assessment of the shoulder. *Clin Orthop Relat Res*. 1987;160-164.
35. Cook KF, Roddey TS, Olson SL, Gartsman GM, Valenzuela FF, Hanten WP. Reliability by surgical status of self-reported outcomes in patients who have shoulder pathologies. *J Orthop Sports Phys Ther*. 2002;32:336-346.
36. Cooper DE, O'Brien SJ, Arnoczky SP, Warren RF. The structure and function of the coracohumeral ligament: an anatomic and microscopic study. *J Shoulder Elbow Surg*. 1993;2:70-77. [http://dx.doi.org/10.1016/1058-2746\(93\)90003-Y](http://dx.doi.org/10.1016/1058-2746(93)90003-Y)
37. Cyriax J. *Textbook of Orthopaedic Medicine: Diagnosis of Soft Tissue Lesions*. Baltimore, MD: Williams & Wilkins; 1970.

38. de Jong BA, Dahmen R, Hogeweg JA, Marti RK. Intra-articular triamcinolone acetone injection in patients with capsulitis of the shoulder: a comparative study of two dose regimens. *Clin Rehabil*. 1998;12:211-215.
39. Diercks RL, Stevens M. Gentle thawing of the frozen shoulder: a prospective study of supervised neglect versus intensive physical therapy in seventy-seven patients with frozen shoulder syndrome followed up for two years. *J Shoulder Elbow Surg*. 2004;13:499-502. <http://dx.doi.org/10.1016/S1058274604000825>
40. Dogru H, Basaran S, Sarpel T. Effectiveness of therapeutic ultrasound in adhesive capsulitis. *Joint Bone Spine*. 2008;75:445-450. <http://dx.doi.org/10.1016/j.jbspin.2007.07.016>
41. Emig EW, Schweitzer ME, Karasick D, Lubowitz J. Adhesive capsulitis of the shoulder: MR diagnosis. *AJR Am J Roentgenol*. 1995;164:1457-1459. <http://dx.doi.org/10.2214/ajr.164.6.7754892>
42. Feleus A, Bierma-Zeinstra SM, Miedema HS, et al. Prognostic indicators for non-recovery of non-traumatic complaints at arm, neck and shoulder in general practice—6 months follow-up. *Rheumatology (Oxford)*. 2007;46:169-176. <http://dx.doi.org/10.1093/rheumatology/kei164>
43. Gabel CP, Michener LA, Burkett B, Neller A. The Upper Limb Functional Index: development and determination of reliability, validity, and responsiveness. *J Hand Ther*. 2006;19:328-348; quiz 349. <http://dx.doi.org/10.1197/j.jht.2006.04.001>
44. Godges JJ, Mattson-Bell M, Thorpe D, Shah D. The immediate effects of soft tissue mobilization with proprioceptive neuromuscular facilitation on glenohumeral external rotation and overhead reach. *J Orthop Sports Phys Ther*. 2003;33:713-718.
45. Griggs SM, Ahn A, Green A. Idiopathic adhesive capsulitis. A prospective functional outcome study of nonoperative treatment. *J Bone Joint Surg Am*. 2000;82-A:1398-1407.
46. Guler-Uysal F, Kozanoglu E. Comparison of the early response to two methods of rehabilitation in adhesive capsulitis. *Swiss Med Wkly*. 2004;134:353-358.
47. Gummesson C, Atroshi I, Ekdahl C. The disabilities of the arm, shoulder and hand (DASH) outcome questionnaire: longitudinal construct validity and measuring self-rated health change after surgery. *BMC Musculoskelet Disord*. 2003;4:11. <http://dx.doi.org/10.1186/1471-2474-4-11>
48. Guyatt GH, Sackett DL, Sinclair JC, Hayward R, Cook DJ, Cook RJ. Users' guides to the medical literature. IX. A method for grading health care recommendations. Evidence-Based Medicine Working Group. *JAMA*. 1995;274:1800-1804.
49. Hand GC, Athanasou NA, Matthews T, Carr AJ. The pathology of frozen shoulder. *J Bone Joint Surg Br*. 2007;89:928-932. <http://dx.doi.org/10.1302/0301-620X.89B7.19097>
50. Hannafin JA, Chiaia TA. Adhesive capsulitis. A treatment approach. *Clin Orthop Relat Res*. 2000:95-109.
51. Harryman DT, 2nd, Sidles JA, Matsen FA, 3rd. Range of motion and oblique translation in the shoulder: the role of the coracohumeral ligament [abstract]. *Trans Orthop Res Soc*. 1990;15:273.
52. Homsy C, Bordalo-Rodrigues M, da Silva JJ, Stump XM. Ultrasound in adhesive capsulitis of the shoulder: is assessment of the coracohumeral ligament a valuable diagnostic tool? *Skeletal Radiol*. 2006;35:673-678. <http://dx.doi.org/10.1007/s00256-006-0136-y>
53. Hudak PL, Amadio PC, Bombardier C. Development of an upper extremity outcome measure: the DASH (disabilities of the arm, shoulder and hand) [corrected]. The Upper Extremity Collaborative Group (UECG). *Am J Ind Med*. 1996;29:602-608. [http://dx.doi.org/10.1002/\(SICI\)1097-0274\(199606\)29:6<602::AID-AJIM4>3.0.CO;2-L](http://dx.doi.org/10.1002/(SICI)1097-0274(199606)29:6<602::AID-AJIM4>3.0.CO;2-L)
54. Hutchinson JW, Tierney GM, Parsons SL, Davis TR. Dupuytren's disease and frozen shoulder induced by treatment with a matrix metalloproteinase inhibitor. *J Bone Joint Surg Br*. 1998;80:907-908.
55. Ide J, Takagi K. Early and long-term results of arthroscopic treatment for shoulder stiffness. *J Shoulder Elbow Surg*. 2004;13:174-179. <http://dx.doi.org/10.1016/S1058274603002799>
56. Jacobs LG, Smith MG, Khan SA, Smith K, Joshi M. Manipulation or intra-articular steroids in the management of adhesive capsulitis of the shoulder? A prospective randomized trial. *J Shoulder Elbow Surg*. 2009;18:348-353. <http://dx.doi.org/10.1016/j.jse.2009.02.002>
57. Johnson AJ, Godges JJ, Zimmerman GJ, Ounanian LL. The effect of anterior versus posterior glide joint mobilization on external rotation range of motion in patients with shoulder adhesive capsulitis. *J Orthop Sports Phys Ther*. 2007;37:88-99. <http://dx.doi.org/10.2519/jospt.2007.2307>
58. Jürgele J, Rannama L, Gapeyeva H, Erelina J, Kolts I, Pääsuke M. Shoulder function in patients with frozen shoulder before and after 4-week rehabilitation. *Medicina (Kaunas)*. 2005;41:30-38.
59. Karelis CH, Bierma-Zeinstra SM, Burdorf A, Verhagen AP, Nauta AP, Koes BW. Social and psychological factors influenced the course of arm, neck and shoulder complaints. *J Clin Epidemiol*. 2007;60:839-848. <http://dx.doi.org/10.1016/j.jclinepi.2006.11.012>
60. Kelley MJ, McClure PW, Leggin BG. Frozen shoulder: evidence and a proposed model guiding rehabilitation. *J Orthop Sports Phys Ther*. 2009;39:135-148. <http://dx.doi.org/10.2519/jospt.2009.2916>
61. Kivimäki J, Pohjolainen T, Malmivaara A, et al. Manipulation under anesthesia with home exercises versus home exercises alone in the treatment of frozen shoulder: a randomized, controlled trial with 125 patients. *J Shoulder Elbow Surg*. 2007;16:722-726. <http://dx.doi.org/10.1016/j.jse.2007.02.125>
62. Kocher MS, Horan MP, Briggs KK, Richardson TR, O'Holleran J, Hawkins RJ. Reliability, validity, and responsiveness of the American Shoulder and Elbow Surgeons subjective shoulder scale in patients with shoulder instability, rotator cuff disease, and glenohumeral arthritis. *J Bone Joint Surg Am*. 2005;87:2006-2011. <http://dx.doi.org/10.2106/JBJS.C.01624>
63. Lee JC, Guy S, Connell D, Saifuddin A, Lambert S. MRI of the rotator interval of the shoulder. *Clin Radiol*. 2007;62:416-423. <http://dx.doi.org/10.1016/j.crad.2006.11.017>
64. Lee JC, Sykes C, Saifuddin A, Connell D. Adhesive capsulitis: sonographic changes in the rotator cuff interval with arthroscopic correlation. *Skeletal Radiol*. 2005;34:522-527. <http://dx.doi.org/10.1007/s00256-005-0957-0>
65. Lee PN, Lee M, Haq AM, Longton EB, Wright V. Periarthritis of the shoulder. Trial of treatments investigated by multivariate analysis. *Ann Rheum Dis*. 1974;33:116-119.
66. Leggin B, Kelley MJ, Pontillo M. Impairments and function in patients with frozen shoulder compared to patients with rotator cuff tendonopathy. *Second International Congress of Shoulder Therapists*. Bahia, Brazil: September 16-20, 2007.
67. Leung MS, Cheing GL. Effects of deep and superficial heating in the management of frozen shoulder. *J Rehabil Med*. 2008;40:145-150. <http://dx.doi.org/10.2340/16501977-0146>
68. Levine WN, Kashyap CP, Bak SF, Ahmad CS, Blaine TA, Bigliani LU. Non-operative management of idiopathic adhesive capsulitis. *J Shoulder Elbow Surg*. 2007;16:569-573. <http://dx.doi.org/10.1016/j.jse.2006.12.007>
69. Linsell L, Dawson J, Zondervan K, et al. Prevalence and incidence of adults consulting for shoulder conditions in UK primary care; patterns of diagnosis and referral. *Rheumatology (Oxford)*. 2006;45:215-221. <http://dx.doi.org/10.1093/rheumatology/kei139>
70. Lorbach O, Kieb M, Scherf C, Seil R, Kohn D, Pape D. Good results after

fluoroscopic-guided intra-articular injections in the treatment of adhesive capsulitis of the shoulder. *Knee Surg Sports Traumatol Arthrosc.* 2010;18:1435-1441. <http://dx.doi.org/10.1007/s00167-009-1030-7>

71. Lundberg BJ. The frozen shoulder. Clinical and radiographical observations. The effect of manipulation under general anesthesia. Structure and glycosaminoglycan content of the joint capsule. Local bone metabolism. *Acta Orthop Scand Suppl.* 1969;119:1-59.
72. MacDermid JC, Drosdowech D, Faber K. Responsiveness of self-report scales in patients recovering from rotator cuff surgery. *J Shoulder Elbow Surg.* 2006;15:407-414. <http://dx.doi.org/10.1016/j.jse.2005.09.005>
73. MacDermid JC, Walton DM, Law M. Critical appraisal of research evidence for its validity and usefulness. *Hand Clin.* 2009;25:29-42. <http://dx.doi.org/10.1016/j.hcl.2008.11.003>
74. Mao CY, Jaw WC, Cheng HC. Frozen shoulder: correlation between the response to physical therapy and follow-up shoulder arthrography. *Arch Phys Med Rehabil.* 1997;78:857-859.
75. Mengiardi B, Pfirrmann CW, Gerber C, Hodler J, Zanetti M. Frozen shoulder: MR arthrographic findings. *Radiology.* 2004;233:486-492. <http://dx.doi.org/10.1148/radiol.2332031219>
76. Michener LA, McClure PW, Sennett BJ. American Shoulder and Elbow Surgeons Standardized Shoulder Assessment Form, patient self-report section: reliability, validity, and responsiveness. *J Shoulder Elbow Surg.* 2002;11:587-594. <http://dx.doi.org/10.1067/mse.2002.127096>
77. Milgrom C, Novack V, Weil Y, Jaber S, Radeva-Petrova DR, Finestone A. Risk factors for idiopathic frozen shoulder. *Isr Med Assoc J.* 2008;10:361-364.
78. Miller MD, Wirth MA, Rockwood CA, Jr. Thawing the frozen shoulder: the "patient" patient. *Orthopedics.* 1996;19:849-853.
79. Mintken PE, Cleland JA, Carpenter KJ, Bieniek ML, Keirns M, Whitman JM. Some factors predict successful short-term outcomes in individuals with shoulder pain receiving cervicotoracic manipulation: a single-arm trial. *Phys Ther.* 2010;90:26-42. <http://dx.doi.org/10.2522/ptj.20090095>
80. Mitchell C, Adebajo A, Hay E, Carr A. Shoulder pain: diagnosis and management in primary care. *BMJ.* 2005;331:1124-1128. <http://dx.doi.org/10.1136/bmj.331.7525.1124>
81. Mueller MJ, Maluf KS. Tissue adaptation to physical stress: a proposed "Physical Stress Theory" to guide physical therapist practice, education, and research. *Phys Ther.* 2002;82:383-403.
82. Neer CS, 2nd, Satterlee CC, Dalsey RM, Flatow EL. The anatomy and potential effects of contracture of the coracohumeral ligament. *Clin Orthop Relat Res.* 1992;182-185.
83. Neviaser AS, Hannafin JA. Adhesive capsulitis: a review of current treatment. *Am J Sports Med.* 2010;38:2346-2356. <http://dx.doi.org/10.1177/0363546509348048>
84. Neviaser JS. Adhesive capsulitis and the stiff and painful shoulder. *Orthop Clin North Am.* 1980;11:327-331.
85. Neviaser JS. Adhesive capsulitis of the shoulder, a study of the pathological findings in peri-arthritis of the shoulder. *J Bone Joint Surg Am.* 1945;27:211-222.
86. Neviaser JS. Arthrography of the shoulder joint: study of the findings in adhesive capsulitis of the shoulder. *J Bone Joint Surg Am.* 1962;44-A:1321-1359.
87. Neviaser RJ. Painful conditions affecting the shoulder. *Clin Orthop Relat Res.* 1983:63-69.
88. Neviaser RJ. Ruptures of the rotator cuff. *Orthop Clin North Am.* 1987;18:387-394.
89. Neviaser RJ, Neviaser TJ. The frozen shoulder. Diagnosis and management. *Clin Orthop Relat Res.* 1987:59-64.
90. Neviaser TJ. Adhesive capsulitis. *Orthop Clin North Am.* 1987;18:439-443.
91. Nicholson GG. The effects of passive joint mobilization on pain and hypomobility associated with adhesive capsulitis of the shoulder. *J Orthop Sports Phys Ther.* 1985;6:238-246.
92. Nicholson GP. Arthroscopic capsular release for stiff shoulders: effect of etiology on outcomes. *Arthroscopy.* 2003;19:40-49. <http://dx.doi.org/10.1053/jars.2003.50010>
93. Oh JH, Oh CH, Choi JA, Kim SH, Kim JH, Yoon JP. Comparison of glenohumeral and subacromial steroid injection in primary frozen shoulder: a prospective, randomized short-term comparison study. *J Shoulder Elbow Surg.* 2011;20:1034-1040. <http://dx.doi.org/10.1016/j.jse.2011.04.029>
94. Omari A, Bunker TD. Open surgical release for frozen shoulder: surgical findings and results of the release. *J Shoulder Elbow Surg.* 2001;10:353-357. <http://dx.doi.org/10.1067/mse.2001.115986>
95. Ovesen J, Nielsen S. Stability of the shoulder joint. Cadaver study of stabilizing structures. *Acta Orthop Scand.* 1985;56:149-151.
96. Ozaki J, Nakagawa Y, Sakurai G, Tamai S. Recalcitrant chronic adhesive capsulitis of the shoulder. Role of contracture of the coracohumeral ligament and rotator interval in pathogenesis and treatment. *J Bone Joint Surg Am.* 1989;71:1511-1515.
97. Pal B, Anderson J, Dick WC, Griffiths ID. Limitation of joint mobility and shoulder capsulitis in insulin- and non-insulin-dependent diabetes mellitus. *Br J Rheumatol.* 1986;25:147-151.
98. Paul A, Lewis M, Shadforth MF, Croft PR, van der Windt DA, Hay EM. A comparison of four shoulder-specific questionnaires in primary care. *Ann Rheum Dis.* 2004;63:1293-1299. <http://dx.doi.org/10.1136/ard.2003.012088>
99. Pearsall AW, Holovacs TF, Speer KP. The intra-articular component of the subscapularis tendon: anatomic and histological correlation in reference to surgical release in patients with frozen-shoulder syndrome. *Arthroscopy.* 2000;16:236-242.
100. Phillips B, Ball C, Sackett D, et al. Oxford Centre for Evidence-based Medicine - Levels of Evidence (March 2009). Available at: <http://www.cebm.net/index.aspx?o=1025>. Accessed July 5, 2009.
101. Placzek JD, Roubal PJ, Freeman DC, Kulig K, Nasser S, Pagett BT. Long-term effectiveness of translational manipulation for adhesive capsulitis. *Clin Orthop Relat Res.* 1998:181-191.
102. Plancher KD, Johnston JC, Peterson RK, Hawkins RJ. The dimensions of the rotator interval. *J Shoulder Elbow Surg.* 2005;14:620-625. <http://dx.doi.org/10.1016/j.jse.2005.02.022>
103. Pouliart N, Somers K, Eid S, Gagey O. Variations in the superior capsuloligamentous complex and description of a new ligament. *J Shoulder Elbow Surg.* 2007;16:821-836. <http://dx.doi.org/10.1016/j.jse.2007.02.138>
104. Rauoof MA, Lone NA, Bhat BA, Habib S. Etiological factors and clinical profile of adhesive capsulitis in patients seen at the rheumatology clinic of a tertiary care hospital in India. *Saudi Med J.* 2004;25:359-362.
105. Reeves B. Arthrographic changes in frozen and post-traumatic stiff shoulders. *Proc R Soc Med.* 1966;59:827-830.
106. Reeves B. The natural history of the frozen shoulder syndrome. *Scand J Rheumatol.* 1975;4:193-196.
107. Richards RR, An KN, Bigliani LU, et al. A standardized method for the assessment of shoulder function. *J Shoulder Elbow Surg.* 1994;3:347-352. [http://dx.doi.org/10.1016/S1058-2746\(09\)80019-0](http://dx.doi.org/10.1016/S1058-2746(09)80019-0)

108. Riddle DL, Rothstein JM, Lamb RL. Goniometric reliability in a clinical setting. Shoulder measurements. *Phys Ther*. 1987;67:668-673.
109. Rizk TE, Christopher RP, Pinals RS, Higgins AC, Frix R. Adhesive capsulitis (frozen shoulder): a new approach to its management. *Arch Phys Med Rehabil*. 1983;64:29-33.
110. Rizk TE, Pinals RS. Frozen shoulder. *Semin Arthritis Rheum*. 1982;11:440-452.
111. Rizk TE, Pinals RS. Histocompatibility type and racial incidence in frozen shoulder. *Arch Phys Med Rehabil*. 1984;65:33-34.
112. Roach KE, Budiman-Mak E, Songsiridej N, Lertratanakul Y. Development of a shoulder pain and disability index. *Arthritis Care Res*. 1991;4:143-149.
113. Rodeo SA, Hannafin JA, Tom J, Warren RF, Wickiewicz TL. Immunolocalization of cytokines and their receptors in adhesive capsulitis of the shoulder. *J Orthop Res*. 1997;15:427-436. <http://dx.doi.org/10.1002/jor.1100150316>
114. Roubal PJ, Dobritt D, Placzek JD. Glenohumeral gliding manipulation following interscalene brachial plexus block in patients with adhesive capsulitis. *J Orthop Sports Phys Ther*. 1996;24:66-77.
115. Roy JS, MacDermid JC, Woodhouse LJ. Measuring shoulder function: a systematic review of four questionnaires. *Arthritis Rheum*. 2009;61:623-632. <http://dx.doi.org/10.1002/art.24396>
116. Rundquist PJ, Anderson DD, Guanche CA, Ludewig PM. Shoulder kinematics in subjects with frozen shoulder. *Arch Phys Med Rehabil*. 2003;84:1473-1479.
117. Ryans I, Montgomery A, Galway R, Kernohan WG, McKane R. A randomized controlled trial of intra-articular triamcinolone and/or physiotherapy in shoulder capsulitis. *Rheumatology (Oxford)*. 2005;44:529-535. <http://dx.doi.org/10.1093/rheumatology/keh535>
118. Schmitt JS, Di Fabio RP. Reliable change and minimum important difference (MID) proportions facilitated group responsiveness comparisons using individual threshold criteria. *J Clin Epidemiol*. 2004;57:1008-1018. <http://dx.doi.org/10.1016/j.jclinepi.2004.02.007>
119. Shaffer B, Tibone JE, Kerlan RK. Frozen shoulder. A long-term follow-up. *J Bone Joint Surg Am*. 1992;74:738-746.
120. Sheridan MA, Hannafin JA. Upper extremity: emphasis on frozen shoulder. *Orthop Clin North Am*. 2006;37:531-539. <http://dx.doi.org/10.1016/j.ocl.2006.09.009>
121. Sökk J, Gapeyeva H, Erelina J, Kolts I, Pääsuke M. Shoulder muscle strength and fatigability in patients with frozen shoulder syndrome: the effect of 4-week individualized rehabilitation. *Electromyogr Clin Neurophysiol*. 2007;47:205-213.
122. Soldatis JJ, Moseley JB, Etmann M. Shoulder symptoms in healthy athletes: a comparison of outcome scoring systems. *J Shoulder Elbow Surg*. 1997;6:265-271.
123. Staples MP, Forbes A, Green S, Buchbinder R. Shoulder-specific disability measures showed acceptable construct validity and responsiveness. *J Clin Epidemiol*. 2010;63:163-170. <http://dx.doi.org/10.1016/j.jclinepi.2009.03.023>
124. Tanaka K, Saura R, Takahashi N, Hiura Y, Hashimoto R. Joint mobilization versus self-exercises for limited glenohumeral joint mobility: randomized controlled study of management of rehabilitation. *Clin Rheumatol*. 2010;29:1439-1444. <http://dx.doi.org/10.1007/s10067-010-1525-0>
125. Turkel SJ, Panio MW, Marshall JL, Girgis FG. Stabilizing mechanisms preventing anterior dislocation of the glenohumeral joint. *J Bone Joint Surg Am*. 1981;63:1208-1217.
126. Uthoff HK, Boileau P. Primary frozen shoulder: global capsular stiffness versus localized contracture. *Clin Orthop Relat Res*. 2007;456:79-84. <http://dx.doi.org/10.1097/BLO.0b013e318030846d>
127. Uitvlugt G, Detrisac DA, Johnson LL, Austin MD, Johnson C. Arthroscopic observations before and after manipulation of frozen shoulder. *Arthroscopy*. 1993;9:181-185. [http://dx.doi.org/10.1016/S0749-8063\(05\)80371-8](http://dx.doi.org/10.1016/S0749-8063(05)80371-8)
128. Vahlensieck M. MRI of the shoulder. *Eur Radiol*. 2000;10:242-249.
129. van der Windt DA, Koes BW, Deville W, Boeke AJ, de Jong BA, Bouter LM. Effectiveness of corticosteroid injections versus physiotherapy for treatment of painful stiff shoulder in primary care: randomised trial. *BMJ*. 1998;317:1292-1296.
130. Vermeulen HM, Obermann WR, Burger BJ, Kok GJ, Rozing PM, van den Ende CH. End-range mobilization techniques in adhesive capsulitis of the shoulder joint: a multiple-subject case report. *Phys Ther*. 2000;80:1204-1213.
131. Vermeulen HM, Rozing PM, Obermann WR, le Cessie S, Vliet Vlieland TP. Comparison of high-grade and low-grade mobilization techniques in the management of adhesive capsulitis of the shoulder: randomized controlled trial. *Phys Ther*. 2006;86:355-368.
132. Wadsworth CT. Frozen shoulder. *Phys Ther*. 1986;66:1878-1883.
133. Watson L, Dalziel R, Story I. Frozen shoulder: a 12-month clinical outcome trial. *J Shoulder Elbow Surg*. 2000;9:16-22.
134. Wiley AM. Arthroscopic appearance of frozen shoulder. *Arthroscopy*. 1991;7:138-143.
135. Wiley AM. Superior humeral dislocation. A complication following decompression and debridement for rotator cuff tears. *Clin Orthop Relat Res*. 1991:135-141.
136. World Health Organization. *ICD-10: International Statistical Classification of Diseases and Related Health Problems: Tenth Revision*. Geneva, Switzerland: World Health Organization; 2005.
137. World Health Organization. *International Classification of Functioning, Disability and Health: ICF*. Geneva, Switzerland: World Health Organization; 2008.
138. Yang JL, Chang CW, Chen SY, Wang SF, Lin JJ. Mobilization techniques in subjects with frozen shoulder syndrome: randomized multiple-treatment trial. *Phys Ther*. 2007;87:1307-1315. <http://dx.doi.org/10.2522/ptj.20060295>
139. Yung E, Asavasopon S, Godges JJ. Screening for head, neck, and shoulder pathology in patients with upper extremity signs and symptoms. *J Hand Ther*. 2010;23:173-185; quiz 186. <http://dx.doi.org/10.1016/j.jht.2009.11.004>
140. Zuckerman JD. Definition and classification of frozen shoulder [abstract]. *J Shoulder Elbow Surg*. 1994;3:S72.



MORE INFORMATION
WWW.JOSPT.ORG

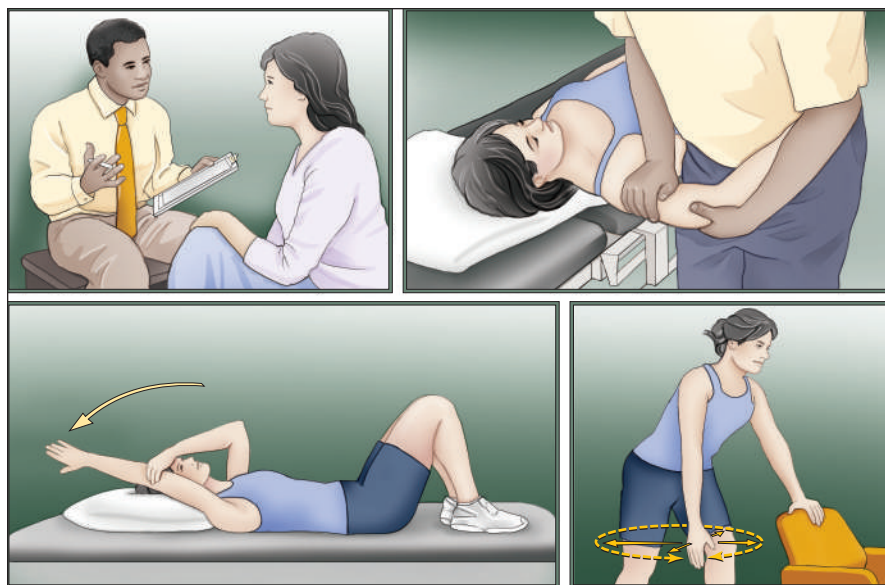
Frozen Shoulder

What Can a Physical Therapist Do for My Painful and Stiff Shoulder?

J Orthop Sports Phys Ther 2013;43(5):351. doi:10.2519/jospt.2013.0503

Frozen shoulder, also known as adhesive capsulitis, refers to a condition where the shoulder becomes painful and stiff. It may occur following a relatively minor injury to the shoulder but most often develops without a clear reason. Frozen shoulder can also be linked to other health problems such as diabetes and thyroid disease. With this condition, the pain and stiffness can limit your ability to do simple everyday activities like getting dressed, brushing your hair, or reaching into a cabinet. The condition affects between 2% and 5% of the population at some point in their lives, and typically occurs in adults between 40 and 65 years of age. The problem usually lasts 1 to 2 years.

People with frozen shoulder usually experience an initial period characterized by an achy shoulder at rest, severe pain with movement, and difficulty sleeping because of shoulder pain. This leads to a progressive loss of motion (“freezing”) and limited function of the shoulder over several months, a time when there is often less pain but greater difficulty performing daily tasks. Eventually, the condition starts to “thaw” and shoulder motion and function gradually return. Recently, a panel of experts developed a set of treatment guidelines for improving the quality of care for people with frozen shoulder. These guidelines are published in the May 2013 issue of *JOSPT*.



FROZEN SHOULDER TREATMENTS. Several treatment options are available to address frozen shoulder. A thorough evaluation will help define the right treatment approach for your shoulder. In addition to education on the condition, your physical therapist will help determine the right combination of stretching and mobility exercises and joint mobilizations to get you on the road to recovery.

For this and more topics, visit *JOSPT* Perspectives for Patients online at www.jospt.org.

This *JOSPT* Perspectives for Patients is based on an article by Kelley MJ et al, titled “Shoulder Pain and Mobility Deficits: Adhesive Capsulitis,” *J Orthop Sports Phys Ther* 2013;43(5):A1-A31. doi:10.2519/jospt.2013.0302.

This Perspectives article was written by a team of *JOSPT*'s editorial board and staff, with Deydre S. Teyhen, PT, PhD, Editor, and Jeanne Robertson, Illustrator.

NEW INSIGHTS

The expert panel recommends that patients learn about the symptoms that suggest they have frozen shoulder, what to expect as the condition progresses, and the timeline for recovery. They also urge that patients continue to use the affected shoulder during daily activities. In addition, participation in a good treatment program that combines education, mobility and stretching exercises, and joint mobilizations performed by your physical therapist can help manage symptoms and lead to faster recovery of your shoulder motion and function. Heat and other treatments applied to the shoulder can also make mobility and stretching exercises more effective. Finally, your physician may suggest a corticosteroid injection for your shoulder. The combination of an injection with joint mobilizations followed by mobility and stretching exercises has been found to be helpful.

PRACTICAL ADVICE

If you have frozen shoulder, making sure you continue to move your shoulder the proper amount is key to your recovery. There are a number of treatment options performed by physical therapists—joint mobilization or manipulation, exercise, and heat, among them—to help speed up your healing. Your physical therapist can help you better understand the condition and, after a thorough evaluation, customize a treatment program that will include exercises for you to perform at home to decrease the pain and improve the motion and function of your shoulder. For more information on the treatment of frozen shoulder, contact your physical therapist specializing in musculoskeletal disorders.



JOSPT PERSPECTIVES FOR PATIENTS is a public service of the *Journal of Orthopaedic & Sports Physical Therapy*. The information and recommendations contained here are a summary of the referenced research article and are not a substitute for seeking proper healthcare to diagnose and treat this condition. For more information on the management of this condition, contact your physical therapist or healthcare provider specializing in musculoskeletal disorders. *JOSPT* Perspectives for Patients may be photocopied noncommercially by physical therapists and other healthcare providers to share with patients. The official journal of the Orthopaedic Section and the Sports Physical Therapy Section of the American Physical Therapy Association (APTA), *JOSPT* strives to offer high-quality research, immediately applicable clinical material, and useful supplemental information on musculoskeletal and sports-related health, injury, and rehabilitation. Copyright ©2013 *Journal of Orthopaedic & Sports Physical Therapy*®

This article has been cited by:

1. Derek Clewley, Timothy W. Flynn, Shane Koppenhaver. 2014. Trigger Point Dry Needling as an Adjunct Treatment for a Patient With Adhesive Capsulitis of the Shoulder. *Journal of Orthopaedic & Sports Physical Therapy* 44:2, 92-101. [[Abstract](#)] [[Full Text](#)] [[PDF](#)] [[PDF Plus](#)] [[Supplemental Material](#)]
2. Guy G. Simoneau, Edith Holmes. 2014. JOSPT at 35. *Journal of Orthopaedic & Sports Physical Therapy* 44:1, 3-5. [[Abstract](#)] [[Full Text](#)] [[PDF](#)] [[PDF Plus](#)]
3. Filip Struyf, Mira Meeus. 2013. Current evidence on physical therapy in patients with adhesive capsulitis: what are we missing?. *Clinical Rheumatology* . [[CrossRef](#)]
4. Philip Paul Tygiel. 2013. December 2013 Letter to the Editor-in-Chief. *Journal of Orthopaedic & Sports Physical Therapy* 43:12, 934-936. [[Citation](#)] [[Full Text](#)] [[PDF](#)] [[PDF Plus](#)]
5. 2013. September 2013 Letter to the Editor-in-Chief. *Journal of Orthopaedic & Sports Physical Therapy* 43:9, 675-678. [[Abstract](#)] [[Full Text](#)] [[PDF](#)] [[PDF Plus](#)]
6. Paula M. Ludewig, Rebekah L. Lawrence, Jonathan P. Braman. 2013. What's in a Name? Using Movement System Diagnoses Versus Pathoanatomic Diagnoses. *Journal of Orthopaedic & Sports Physical Therapy* 43:5, 280-283. [[Abstract](#)] [[Full Text](#)] [[PDF](#)] [[PDF Plus](#)]